



# Congenital candida cases in a level-3 neonatal intensive care unit - A 10-year review

Brandi Newby<sup>1,2</sup> , Anithadevi Moodley<sup>1</sup> , Jacqueline Clayton<sup>1</sup> , Cherrie Tan-Dy<sup>1</sup> 

<sup>1</sup> Surrey Memorial Hospital, Department of Neonatal Intensive Care Unit and Pharmacy, Surrey, Canada

<sup>2</sup> Surrey Memorial Hospital, Neonatal and Pediatric Pharmacy, Surrey, British Columbia, Canada

## Abstract

**Objective:** Describe the changing clinical pattern of congenital candida infection in our Neonatal Intensive Care Unit and raise awareness of the opportunity for prevention by identifying and treating candida infections during pregnancy.

**Case(s):** We report 6 cases (6/4900, 0.12%) of congenital candida infection, which exceeded our number of cases of acquired invasive yeast infections (2/4900, 0.04%). Five of the cases were in preterm neonates, and 4 had a birth weight less than 1500 grams. Membranes were intact at delivery for 4 of the cases, though 5 of the birthing parents had yeast present at the time of delivery. The first sign of infection was a rash noted on the day of birth for 4 of the cases, and the rash covered a significant portion of the body in all 6 cases. Sloughing of the skin occurred in all cases at approximately day of life 6. Antifungal treatment was started within the first 10 days for all of the cases. For these 6 cases there was 83% survival, despite 67% of the patients having disseminated congenital candida infection.

**Conclusion:** Congenital candida infection is under-recognized due to inconsistent clinical presentations and low incidence. Recognition and treatment for pregnant patients with vulvovaginal candidiasis can reduce the risk of congenital candida infection. Clinicians need to consider congenital candida infection when a neonate presents with a rash in the first few days of life. Timely antifungal therapy can minimize life-threatening complications.

**Keywords:** Candida, congenital, antifungal

## Introduction

Pregnant people are at higher risk of colonization and infection with candida due to changes in hormones and the immune system that occur during pregnancy. With these changes, up to 75% of people in child bearing years may experience a vaginal candida infection.<sup>[1]</sup> In pregnancy, untreated vaginal candidiasis can cause local or disseminated neonatal disease by ascending infection. Risk factors in pregnancy that increase the risk of congenital candida infection for the neonate include: maternal fungal vaginosis, rupture of membranes, prolonged rupture of membranes, vaginal birth, preterm birth, low birth weight, diabetes and use of medications that can impact the immune system.<sup>[2-4]</sup> Georgescu et al identified 44

cases of congenital candida in a meta-analysis spanning 54 years.<sup>[5]</sup> Though these infections are rare, they are associated with high morbidity and mortality rates.<sup>[5,6]</sup> This case series, presents our Neonatal Intensive Care Unit's (NICU) experience to increase awareness of diagnosis and management options that highlight the importance of identifying and treating candida infections during pregnancy to prevent complications for neonates.

## Case(s)

We conducted a review of the prescriptions for systemic antifungals and cultures positive for yeast between November 1, 2014 and October 31, 2024 in the Surrey Memorial Hospital NICU, a 32 bed NICU in Surrey, British Columbia, Canada. There were 23 patients that

**Correspondence:** Brandi Newby, **e-mail:** brandi.newby@fraserhealth.ca, **Received:** February 17, 2025 **Accepted:** March 18, 2025

**How to cite this article:** Newby B, Moodley A, Clayton J, Tan-Dy C. Congenital candida cases in a level-3 neonatal intensive care unit - A 10-year review. Perinatal Journal 2025;33(1):40-45 DOI: 10.59215/prn.24.0323008

**ORCID ID:** B Newby 0000-0002-5123-5841; A Moodley A; J Clayton 0000-0002-8546-591X; C Tan-Dy

received systemic antifungal therapy including 6 cases of congenital candida. (Table 1) During this time period, there were approximately 4900 NICU admissions. The rate of congenital candida, 0.12% (6/4900), exceeded the rate for hospital acquired invasive yeast infections in the NICU, 0.04% (2/4900). For neonates with a birthweight less than 1500 grams, there were 785 neonates and 4 had a congenital candida infection, with an incidence of 0.5%. Informed consent was obtained from the parents of case 1, 2, and 3 to share their NICU course and the images of the congenital candida rash. As the other cases were historical consent was not obtained.

Case 1 was born at 28 + 3/7 weeks gestation with a birthweight of 1284 grams via emergency caesarean delivery for suspected abruption. At birth, there was no report of

the birth parent having a current yeast infection. However, when asked by the health care team in the NICU a few days later, the birthing parent reported symptoms of discharge consistent with vulvovaginal candidiasis for several weeks prior to delivery, which was not diagnosed or treated by her physician. (Table 2)

**Table 1.** Review of Systemic Antifungal Use in NICU over 10 years

Patients (n=23)	Positive Culture	Source
12	No	Empiric Use
3	Yes	Persistent topical infection (mouth or diaper area)
1	Yes	Urine
1	Yes	Lungs
6	Yes	Congenital

**Table 2.** Birthing Parent and Neonatal Characteristics

Birthing Parent Characteristics											
Case	Tested for yeast	Yeast present	Yeast treated	NICU aware of yeast at birth	ROM	Delivery		Preterm birth	Diabetes	Steroids	
1	No	Yes*	No	No	No	ER CS		Yes	No	No	
2	No	?	No	No	No	ER CS		Yes	No	Yes	
3	Yes	Yes	No	Yes	Yes	SVD		Yes	Yes	No	
4	Yes	Yes	No	Yes	No	ER CS		No	No	No	
5	Yes	Yes	No	No	No	SVD		Yes	No	No	
6	Yes	Yes	No	No	Yes	SVD		Yes	Yes	Yes	
Neonatal Characteristics											
Case	GA (wks)	Male gender	BW (g)	CVC	DOL start	Drug	Route	Dose (mg/kg)	Treatment	Outcome	
1	28+3	Yes	1284	Yes			4	AmB Flucon	IV PO	49 252	Survived
2	23+1	Yes	696	Yes			10	Flucon AmB Flucyt	IV IV PO	72 49 575	Survived
3	28+6	Yes	1316	Yes			0	Flucon AmB	IV/PO IV	109 9	Survived
4	39+5	Yes	3672	No			0	Flucon Flucon	IV PO	168 84	Survived, readmitted
5	23	No	510	Yes			8	Flucon	IV	12	Died
6	30+2	No	1710	Yes			4	Flucon	IV	120	Survived

\* yeast present based on clinical symptoms; ER CS = emergency caesarean section; SVD = spontaneous vaginal delivery; AmB = amphotericin B; Flucon = fluconazole; Flucyt = flucytosine

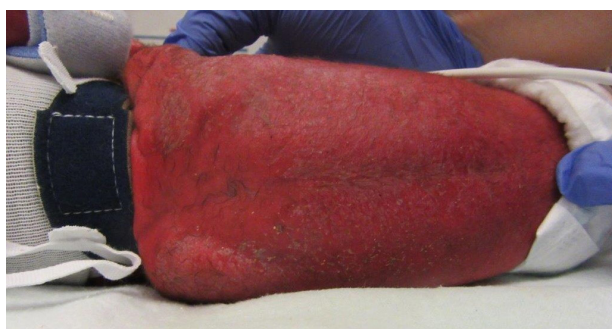At birth, the neonate had a maculopapular skin rash on the trunk with desquamation on the back. (Figure 1) Vancomycin was started given the extensive skin rash initially thought to be staphylococcal in nature. On day 4 of life, the rash was maculopapular with satellite lesions (Figure 2). The head ultrasound revealed lesions suspicious for fungal balls, therefore amphotericin B 1 mg/kg intravenously daily was initiated. Skin cultures and the umbilical arterial catheter tip were positive for candida albicans. (Table 3) The skin started peeling on day of life 6 (Figure 3). A series of abdominal ultrasounds showed multiple hepatic micro-abscesses that appeared consistent with fungal infection. Given the extensive skin involvement

as well as suspected blood, brain and liver involvement, disseminated congenital candida was diagnosed. Ophthalmologic exam did not find evidence of candida. Evidence of candida skin rash remained on day of life 34 (Figure 4) and pustules on the face and abdomen remained until discharge. Amphotericin B was continued at 1 mg/kg intravenously for 7 weeks, then changed to fluconazole 24 mg/kg orally for one dose followed by 12 mg/kg orally daily for 19 days. The neonate was treated with antifungals for a total of 10 weeks. He was discharged home at post menstrual age of 40 + 4/7 weeks in room air and taking full enteral feeds.

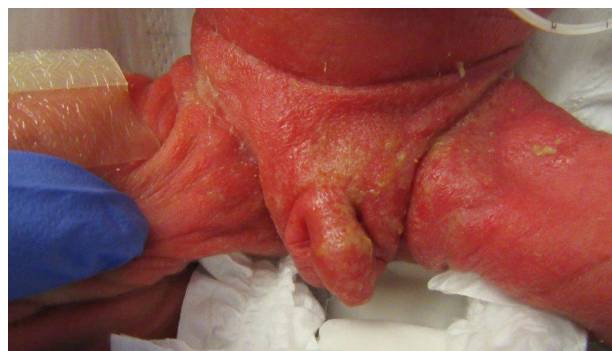**Table 3.** Congenital Candida Characteristics

Case	Source	Organism	Day of positive culture	Description of Skin Lesions			DOL sloughing
				DOL rash noted	Maculopapular	Location	
1	Skin, arterial line, CSF, liver	Candida albicans	5	0	Yes	Trunk, back	6
2	Skin, blood	Candida albicans	9	0	No	Armpits, Extensive	6
3	Skin	Candida albicans	0	0	Yes	Extensive	10
4	Skin, heart, placenta	Candida albicans	1	0	Yes	Extensive	7
5	Skin, blood	Candida albicans	9	3	No	Extensive	4
6	Skin, placenta	Candida albicans	5	1	No	Eyes, extensive	6

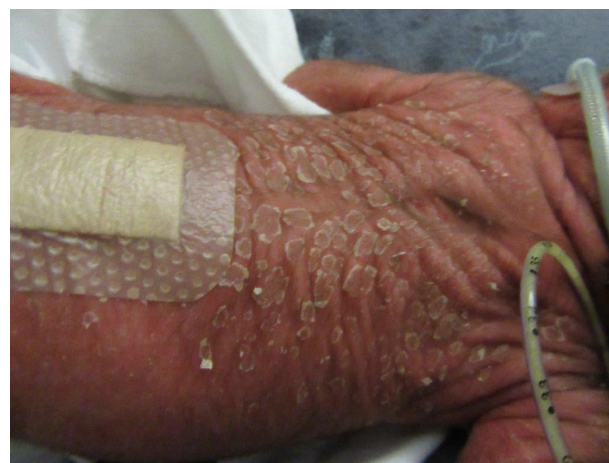DOL = day of life; CSF = cerebral spinal fluid



**Fig 1.** Case 1 - rash day 1 of life



**Fig 2.** Case 1 - rash day of life 4

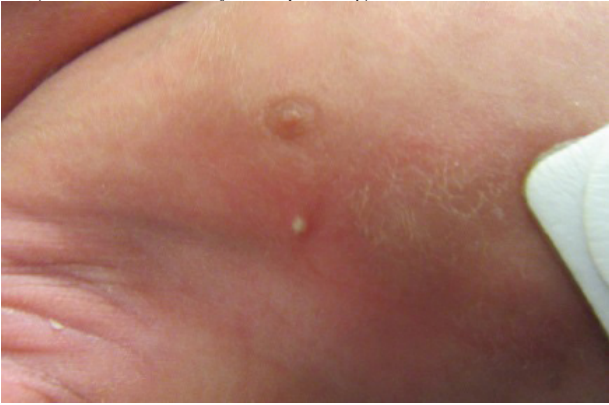

**Fig 3.** Case 1 - rash day of life 14

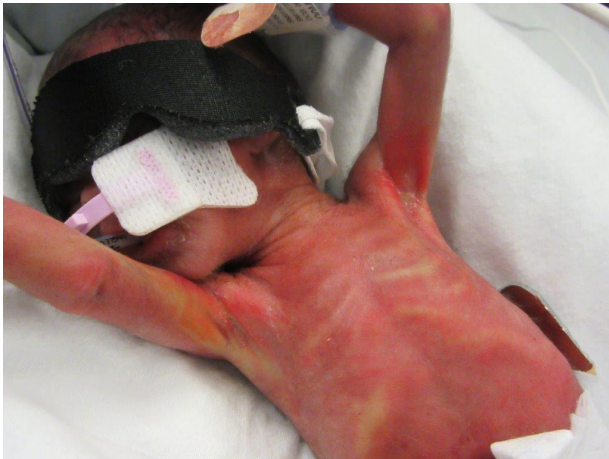Case 2 was born at 23 + 1/7 weeks gestation with a birthweight of 696 grams via emergency caesarean delivery for suspected abruption.

At birth the skin was noted to be fragile and edematous. On day of life 1, the right axilla had weeping clear yellow secretions and vancomycin was started for possible staphylococcal skin infection. On day of life 2, it was noted that there were weeping ulcers near both axilla. (Figure

5) On subsequent days, the rash spread to the rest of the body with many areas having open skin lesions. On day of life 6, the skin was dry and peeling.



**Fig 4.** Case 1 - rash day of life 34



**Fig 5.** Case 2 - rash on day of life 2

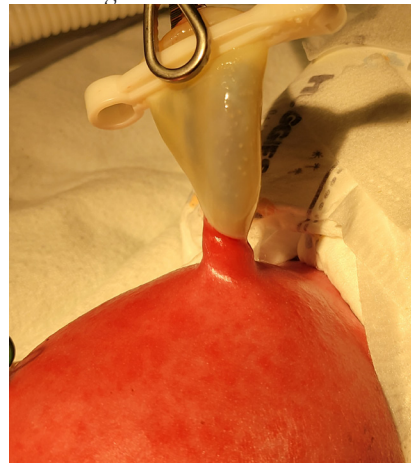
Blood cultures on day of life 9 and 10 were positive for candida albicans and fluconazole 12 mg/kg/day intravenously was initiated on day of life 10. The skin at this time was dry and peeling over the entire body and scalp. The blood cultures remained positive for candida albicans for the next 5 days, despite the candida being sensitive to fluconazole. On day of life 16 fluconazole was discontinued and amphotericin B 1 mg/kg/day intravenously was started.

Blood cultures remained positive for candida for the next 5 days, so one week of flucytosine 25 mg orally every 12 hours for 3 days, then 25 mg orally every 8 hours for 4 days was added. Given the extensive rash and positive blood cultures, disseminated congenital candida was diagnosed. An echocardiogram, abdominal and head ultrasounds obtained during treatment did not show evidence of fungus. The neonate received 8 weeks of antifungal therapy,

with 49 days of amphotericin B. Following completion of antifungal therapy, the neonate developed cataracts which were diagnosed by the ophthalmologist, though it is unknown if they were related to the yeast infection. He had a large intraventricular hemorrhage with post hemorrhagic ventricular dilation that did not require drainage. At 49 weeks post menstrual age, he was discharged home with nasogastric feeds and home oxygen.

Case 3 was born at 28 + 6/7 weeks gestation with a birthweight of 1316 grams via spontaneous vaginal delivery.

At birth there was an extensive maculopapular rash that included the trunk, limbs, face, and eyelids. There were also white pustules on the umbilical cord. (Figure 6) Amphotericin B 1 mg/kg intravenously daily was started on the day of birth. The skin swabs for yeast were positive for candida albicans. An echocardiogram, abdominal and head ultrasound obtained during treatment did not show evidence of fungus. Ophthalmologic assessment did not show any evidence of candida. The rash improved significantly over the next few days and the skin was noted to be dry and peeling on day of life 10. Amphotericin B was given for 9 days, then changed to fluconazole 25 mg/kg intravenously once, followed by 12 mg/kg orally daily for 7 days for a total treatment duration of 14 days. At 38 + 1 weeks post menstrual age, he was discharged home in room air and taking full enteral feeds.



**Fig 6.** Case 3 - rash at birth

Case 4 was born at 39 + 5/7 weeks gestation, with a birthweight of 3672 grams via emergency caesarean delivery for non-reassuring fetal heart.

At birth, he had a generalized erythematous maculopapular rash with scattered papules and vesicles, morbilliform type, extending to the palms and soles.

He was started on fluconazole 12 mg/kg intravenously

daily on the day of birth. On day of life 6, an echocardiogram showed echogenicity near the mitral valve and endocarditis could not be ruled out. On day of life 7, the skin was rough with areas of thickened skin on the face and creases, patchy redness and moderate to severe peeling. Abdominal and head ultrasound obtained during treatment did not show evidence of fungus. Ophthalmologic assessment did not show any evidence of candida. He was discharged home on day of life 13 with fluconazole 12 mg/kg orally daily and plans to follow up with the cardiologist in the community. He received 3 weeks of fluconazole. He was readmitted to a pediatric hospital a few days after stopping fluconazole as he developed another skin rash consistent with candida infection. He was also diagnosed at that time with infectious endocarditis secondary to cutaneous candida, therefore disseminated congenital candida infection, and was managed with fluconazole 12 mg/kg intravenously daily for 6 weeks until the lesion on the mitral valve resolved.

Case 5 was born at 23 weeks gestation with a birthweight of 510 grams via spontaneous vaginal delivery.

On day of life 3, she was noted to have very fragile skin that was bleeding from multiple areas. On day of life 4, there was extensive skin breakdown with serosanguinous drainage. On day of life 6, the skin rash became purpura. A wound care nurse was consulted on day of life 7 due to the extensive skin lesions (Figure 7). On day of life 8, a repeat blood culture was drawn, and fluconazole 12 mg/kg intravenously daily was started empirically for critical illness. The neonate had a hemodynamically significant patent ductus arteriosus requiring pharmacotherapy, which subsequently had to be held due to significant thrombocytopenia requiring 10 platelet transfusions. The infant had ongoing bleeding and a grade 3 intraventricular hemorrhage causing significant hypotension needing intervention with 3 blood transfusions, inotropes and hydrocortisone. The patient died on day of life 9. Her day 8 blood culture was reported to be positive for candida albicans after her death. No diagnosis of candida infection was made during the patient admission, however in retrospect this was a case of unrecognized disseminated congenital candida infection.

Case 6 was born at 30 + 2/7 weeks gestation with a birthweight of 1710 grams via spontaneous vaginal delivery.

Empiric ampicillin and gentamicin were initiated and continued for 5 days due to elevated white blood cell count of  $61 \times 10^9/L$ , with negative blood cultures. On day of life 1, she had skin peeling around the eyes with symmetric mild periorbital erythema, swelling, and desquamation of the superficial cutaneous layer, which was not

associated with eye discharge. On day of life 4, the rash extended over the entire body and fluconazole 12 mg/kg intravenously daily was started. Skin scrapings and placenta culture were positive for candida and therefore she was considered to have congenital candida infection. On day of life 6, her skin began sloughing and she became clinically unwell. She was lethargic and febrile, therefore a full septic work up was completed. The blood culture was positive for *Escherichia coli*, requiring a 14 day course of cefotaxime. A head ultrasound obtained during treatment did not show evidence of fungal balls. For the yeast infection, she received a 10 day course of fluconazole. Once she recovered she was transferred to another health authority before discharge.

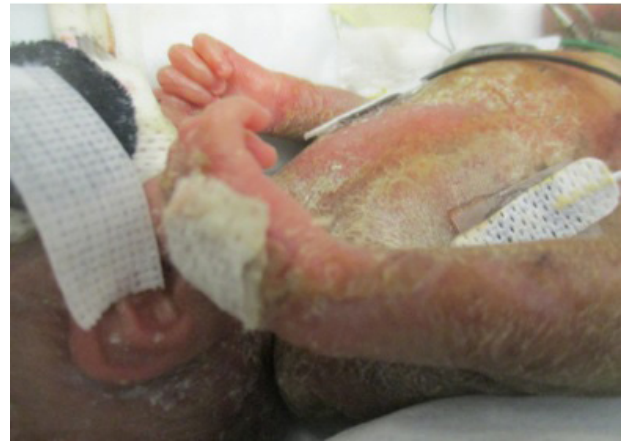

Fig 7. Case 5 - rash on day of life 7

## Discussion

Over the 10-year period, the incidence of congenital candida in our NICU was 0.12%, with 0.5% for very low birth weight neonates, which is consistent with the rate reported by Kaufman et al.<sup>2</sup> Despite disseminated congenital candida infections for 4 of the 6 cases we identified, the 83% survival in this report is higher than the case series by Georgescu et al.<sup>15</sup> These authors found the survival of potentially viable neonates was 44%.<sup>15</sup> Kaufman et al had a 95% survival in their case series, although only about 15% of their patients had disseminated disease.<sup>12</sup> Sanchez-Padilla et al reported mortality rates of 40% for neonates less than 1000 grams, 15% for 1000 to 2500 grams, and 4% for more than 2500 grams, and suggested that early treatment is an important factor in survival.<sup>17</sup> Amphotericin B was reported by Daniel et al to be a first line antifungal for invasive candida infections, and was used in half of our cases.<sup>18</sup>

In this case series, each patient presented with a different appearance of the rash, which delayed the diagnosis and treatment in 67% of the cases. All of the patients in this

case series developed sloughing of the skin starting on approximately day of life 6. Skoczylas et al also reported that skin can peel off all over the body.<sup>[4]</sup> Sanchez-Padilla reported that skin lesions appear on the first day of life in 80% of cases, and usually disappear by 2 weeks of life, with peeling.<sup>[7]</sup> Invasive infections have been associated with fungal involvement of the dermis and epidermis, and can present as burn-like dermatitis, similar to the initial rash observed in case 1.7. When congenital candida is suspected additional screening should be considered to determine if the yeast infection is disseminated including abdominal and head ultrasounds, echocardiography, and ophthalmologic exams.

Premature rupture of membranes is thought to be a risk factor for congenital candida infections, although only two of our patients had rupture of membranes prior to delivery, and for one the rupture was only 1 hour prior to delivery. Candida can reach the fetus through invasion and penetration of intact membranes, spread through the placenta, or by direct contact during delivery.<sup>4,7</sup> Recognition and treatment for pregnant patients with vulvovaginal candidiasis is therefore important to reduce the risk of congenital candida infection. Diagnosis can be made by obtaining a vaginal swab from pregnant women with symptoms or those presenting for possible preterm delivery. In this case series, all of the women that were tested had yeast present at the time of delivery, though none were treated. Van Schalkwyk et al have stated that in pregnancy, vulvovaginal candidiasis can be prolonged and associated with more severe symptoms.<sup>[9]</sup> Topical azoles are the antifungals of choice and may be required for up to 14 days.<sup>[9]</sup>

## Conclusion

Congenital candida infection may be under-recognized due to different clinical presentations, lack of maternal risk factors, and low incidence, although in our NICU congenital candida infection was more prevalent than hospital acquired invasive candida infections. Clinicians need to consider congenital candida infection when a neonate presents with a rash in the first few days of life and start antifungal therapy as soon as possible to minimize life-threatening complications.

## References

1. Disha T, Haque F. Prevalence and Risk Factors of Vulvovaginal Candidosis during Pregnancy: A Review. *Infect Dis Obstet Gynecol.* 2022;2022:6195712. [[PubMed](#)] [[CrossRef](#)]
2. Kaufman DA, Coggins SA, Zanelli SA, Weitkamp JH. Congenital cutaneous candidiasis: prompt systemic treatment is associated with improved outcomes in neonates. *Clinical Infectious Diseases.* 2017;64(10):1387-95 [[PubMed](#)] [[CrossRef](#)]
3. de Leon EM, Jacober SJ, Sobel JD, Foxman B. Prevalence and risk factors for vaginal Candida colonization in women with type 1 and type 2 diabetes. *BMC Infect Dis.* 2002;2:1. [[PubMed](#)] [[CrossRef](#)]
4. Skoczylas MM, Walat A, Kordek A, Loniewska B, Rudnicki J, Maleszka R, Torbe A. Congenital candidiasis as a subject of research in medicine and human ecology. *Annals of Parasitology.* 2014; 60(3): 179-189.
5. Georgescu TA, Lisievici AC, Munteanu O, Furtunescu FL, Bratu OG, Berceanu C, Bohiltea RE. Congenital systemic candidiasis: a comprehensive literature review and meta-analysis of 44 cases. *ROM J Morphol Embryol.* 2020; 61(3):673-680. [[PubMed](#)] [[CrossRef](#)]
6. Monteiro DR, Ferreira AB, Quaresma L, Ferreira I, Azevedo M, Andrade T. Congenital candidiasis – a rare cause of skin eruption. *Acad J Ped Neonatol.* 2021; 10(5): AJP.N.MS.ID.555853 [[CrossRef](#)]
7. Sánchez-Padilla, AP, Valencia-Herrera AM, Toledo-Bahena ME, Mena-Cedillos CA, Duarte-Abdala M, Salazar-Garcia M, Bonifaz A. Congenital Cutaneous Candidiasis: Uncommon Entity or Underdiagnosed? *Current Fungal Infection Reports.* 2019; 13: 175-180. [[CrossRef](#)]
8. Daniel K, Greenberg RG, Boutzoukas A, Katakam L. Updated perspectives on the diagnosis and management of neonatal invasive candidiasis. *Research and Reports in Neonatology.* 2023;13; 45-63. [[CrossRef](#)]
9. Van Schalkwyk J, Yudin MH, et al. Vulvovaginitis: screening for and management of trichomoniasis, vulvovaginal candidiasis, and bacterial vaginosis. *J Obstet Gynaecol Can* 2015;37(3):266–274. [[PubMed](#)] [[CrossRef](#)]