

Ovarian cyst rupture during real-time transvaginal Doppler ultrasonography

Mekin Sezik

Department of Obstetrics and Gynecology, Faculty of Medicine, Süleyman Demirel University, Isparta, Turkey

Abstract

Objective: To present a case of ovarian cyst rupture during transvaginal Doppler ultrasound examination.

Case: A 46-year-old woman with abdominal pain referring to right groin was evaluated with abdominal ultrasonography and presented at our clinic due to a hypoechoic, nonseptated ovarian cyst with regular borders of approximately 7 cm in diameter. Following abrupt and intense pelvic pain starting with the transvaginal scan, the color Doppler revealed high velocity and irregular flow from the posterior cervicouterine wall toward the Pouch of Douglas; then, the patient's pain rapidly regressed.

Conclusion: To the best of our knowledge, this is the first report revealing real-time spontaneous rupture of a "simple" ovarian cyst during Doppler sonography.

Key words: Ovarian cyst rupture, Doppler ultrasonography.

Gerçek zamanlı transvajinal Doppler ultrasonografi esnasında over kist rüptürü

Amaç: Transvajinal Doppler ultrasonografik muayene sırasında gerçekleşen over kist rüptürünün sunulması.

Olgu: Sağ kasığına vuran karın ağrısı nedeni ile abdominal ultrasonografi ile değerlendirilen 46 yaşındaki kadın hastada yaklaşık 7 cm pelvik çapında düzgün cidarlı, hipoekoik, septasız over kisti saptanması üzerine kliniğimize sevk edilmişti. Transvajinal ultrasonografi başlangıcında, ani ve keskin ağrı ile servikouterin arka duvardan Douglas boşluğuna doğru hızlı ve düzensiz Doppler akım saptandı; sonrasında, hastanın ağrısı hızla geriledi.

Sonuç: Ulaşılabildiğimiz kadarı ile "basit" over kistinin spontane rüptürü ilk kez gerçek zamanlı olarak, Doppler ultrasonografi ile kayıt altına alınmış olmaktadır.

Anahtar sözcükler: Over kist rüptürü, Doppler ultrasonografi.

Introduction

In acute pelvic pain cases, transvaginal ultrasonography (TV-USG) becomes the most essential and practical examination method. TV-USG also has a special importance in differential diagnosis of gynecologic and other etiologies of women who refer to clinics for pelvic pain.^[1] TV-USG is also required for distinguishing normal intrauterine pregnancies from cases such as abort or ectopic pregnancy. Becoming widespread and portable of ultrasonography devices and decrease of costs makes TV-USG a standard for the examination of pelvic pain especially of women who are sexually active.^[2]

Usually, Doppler is a routine option offered in ultrasonography devices released to the market especially during the last decade. Sonographic color Doppler practices also can be used for differential diagnosis of different pelvic pathologies. For example, hemorrhagic corpus luteum cysts that may cause pelvic pain are revealed by peripheral Doppler blood flow with low vascular resistance.^[3,4] This typical "fire circle" view mostly helps to establish diagnosis. Therefore, using color Doppler during TV-USG –at least in some cases– is expected to increase diagnostic precision.

In this study, we presented a "simple" ovarian cyst rupture during TV-USG in a women referred to us for

Correspondence: Mekin Sezik, MD. Süleyman Demirel Üniversitesi Tıp Fakültesi Kadın Hastalıkları ve Doğum A.D. 32260 Isparta, Turkey.
e-mail: msezik@yahoo.com

Received: November 10, 2012; **Accepted:** November 28, 2012

Available online at:
www.perinataljournal.com/20120203005
doi:10.2399/prn.12.0203005
QR (Quick Response) Code:



acute pelvic pain. Color Doppler diagnoses during ultrasonographic examination were also recorded. As far as we accessed through ULAKBİM Turkish Medicine Index, PubMed, Scopus and Google Academic Internet database, there is no record about real-time display of ovarian cyst rupture. Based on our case report, we have discussed up-to-date data on ovarian cyst ruptures.

Case Report

A 46-year-old woman (gravida 3, para 2) referred to the emergency service of our hospital due to bottom quadrant pain referring to right groin on 22nd day of menstrual cycle. In her transabdominal ultrasonography, 68x72 mm cystic mass defined as “simple” was found on right adnexal area which had regular borders, in hypoechoic appearance and was nonseptated. Then, consultation was requested from the Department of Obstetrics and Gynecology.

There were 2 normal vaginal deliveries without any complication in the anamnesis of the patient, it was stated that her menarche age was 15 and her menstrual periods were regular (lasting for 5 days with 27 days of intervals). There was no significant characteristic or surgery in obstetric and gynecologic anamnesis of the patient. Full blood count, routine blood biochemistry values and full urine examination parameters of patient

during admittance were found within normal ranges. Serum beta-hCG (human chorionic gonadotrophin) value was 3 mIU/mL (values below 10 mIU/mL were negative). The patient did not mention about any allergy history.

First, TV-USG examination was planned due to the consultation reason. In TV-USG examination (5-8 mHz multi-frequency vaginal probe, Voluson Expert, GE Healthcare, Zipf, Austria), hypoechoic ovarian cyst which was 7 cm in diameter was found in right adnexal area. Then, color Doppler ultrasonographic examination was performed. However, in the meantime, an abrupt and intense pelvic pain developed. Transvaginal Doppler sonography revealed a rapid and irregular flow from the posterior cervicouterine wall towards the Pouch of Douglas (**Fig. 1**). Secondary “aliasing” artifacts appeared during turbulence with high velocity (**Fig. 2**). When rupture cyst content was discharged, an effusion view appeared gradually within the Pouch of Douglas which did not exist in the beginning of the examination (**Fig. 3**). One minute later, intense pain of the patient started to regress. In the meantime, it was found that Doppler flow stopped completely. At this stage, both adnexal areas seemed normal in transvaginal imaging; cystic mass in the ovary disappeared and there was apparent fluid echogenicity in the Pouch of Douglas.

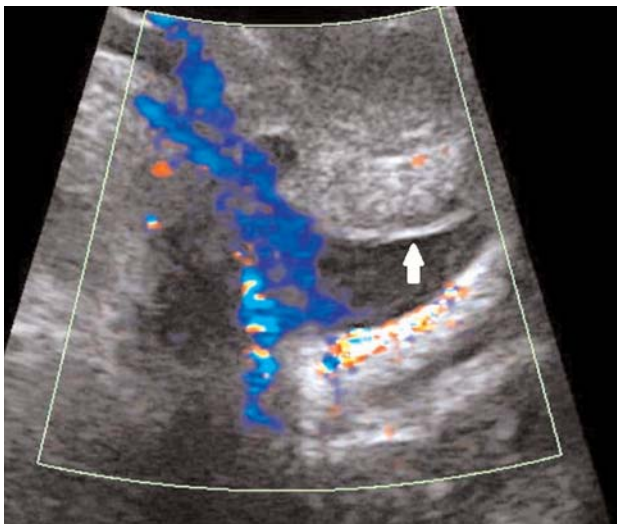


Fig. 1. Fluid substance begins to discharge into the pouch of Douglas rapidly when cyst rupture occurs. Arrow: posterior wall of uterus.

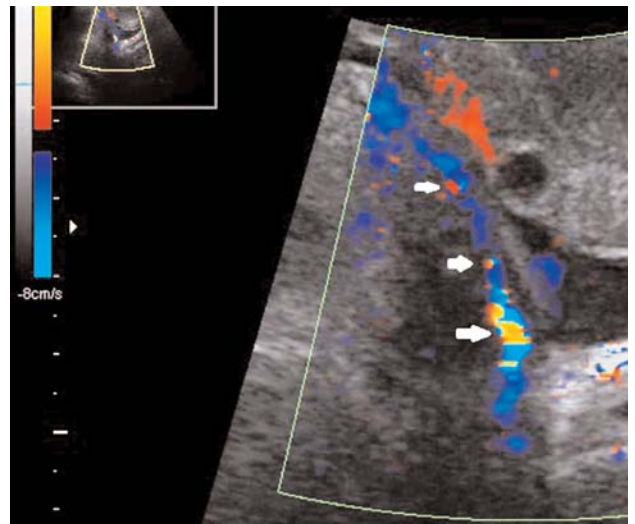


Fig. 2. When cyst content continues to discharge, aliasing artifacts associated with turbulence flow appear (arrows).

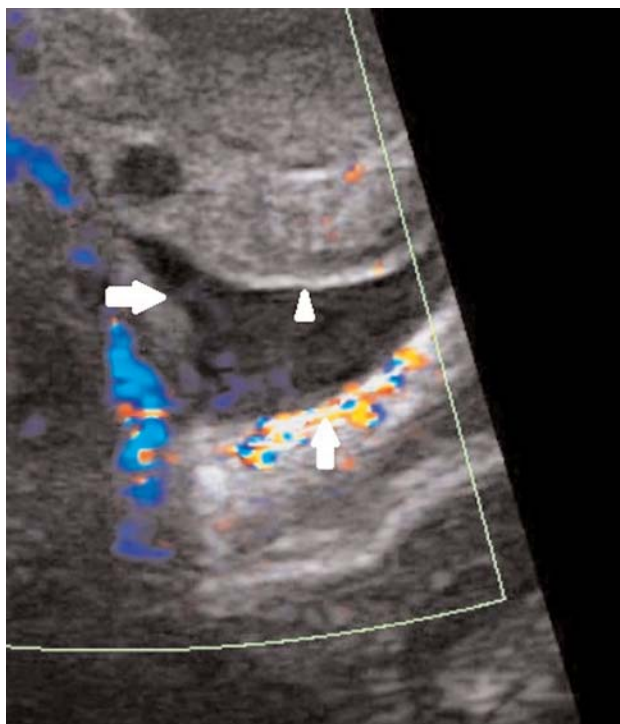


Fig. 3. The increased fluid amount in the pouch of Douglas (margins are shown by arrows) is remarkable when current flow slows down. Triangle arrow head: posterior wall of uterus.

The patient was hospitalized in the Department of Obstetrics and Gynecology by the diagnosis of “ovarian cyst rupture”. Her pulse, blood pressure and hematocrit follow-ups were carried out once in every six hours. The patient was discharged with full recovery after 48 hours when it was observed that her clinical and laboratory findings stable. In the check performed four weeks later, she had normal pelvic and transvaginal ultrasonographic findings.

Discussion

The term “ovarian cyst accidents” is used for bleeding (hemorrhagic) ovarian cysts, ovary torsion, and cyst rupture.^[5] These “accidents” are seen frequently in clinics. Also, “simple” ovarian cysts are frequently seen especially during perimenopausal period. In a relatively recent autopsy study, this rate was found as 18% in postmenopausal period;^[6] ovarian cyst was found approximately in 7% of asymptomatic women between 25 and 40 years old during transvaginal ultrasonographic examination.^[7] In another series where gynecologic

acute abdomen cases were evaluated, it was reported at approximately 22% of applications had at least one ovarian cyst at or above 5 cm in size.^[8]

Ovarian cystic formations with thin wall which are observed as unilocular, relatively anechoic or hypoechoic, and do not include septation or papillary structure are called “simple ovarian cyst”. Most of them consist of anovulatory –and therefore not regressing– ovarian follicles which cannot perform oocyte disposal in menstrual cycle.^[9] Mostly, follicles over 25–30 mm in diameter are referred as “cyst”.^[10] Sometimes, serous or mucinous ovarian cystadenomas are also may be seen as “simple cyst” as defined above. It is known that spontaneous rupture develops in some “simple” ovarian cysts. In such cases, abrupt inferior abdominal pain and frequently nausea or vomiting is seen. In our case, nausea or vomiting was not accompanying to intense pain which disturbing the patient noticeably. Actually, beginning characteristics of the pain may be significant for distinguishing ovarian cyst rupture and ovarian torsion cases: while rupture pain is abrupt and mostly intense, secondary torsion pain is generally gradual.^[5]

In ovarian cyst ruptures (unless no bleeding), it should be expected that severe clinical picture during rupture rapidly regress, and most patients do not have any clinical findings except mild peritonism. However, since preshock findings may appear lately in especially a health woman, it is recommended to follow-up diagnoses such as tachycardia and orthostatic hypotension.^[5] We planned hospitalization in our case and followed-up her vital findings closely; also we evaluated whether there was any reduce in her hematocrit values.

Although major persisting follicle cysts are responsible for most of the ruptures, benign cystadenomas also may be ruptured. It is believed that the long-term effects of serous cyst ruptures are negligible.^[5] Even though mucinous ovarian cyst ruptures are associated with “pseudomyxoma peritonei”, it is agreed that they are secondary to appendix associated mucinous epithelial tumors.^[11] Consequently, short-long term prognosis after “simple” cyst ruptures seems good. It is not known whether repeating abdominal physical examinations or transvaginal ultrasonography increases rupture risk or not. It is known that functional ovarian cysts sometimes cause secondary rupture during excessive physical activity.^[12] However, there is no prospective data presenting this association.

In the emergency medicine literature, ovarian cyst ruptures following blunt abdominal trauma have been defined. In one case, severe intraabdominal bleeding secondary to ovarian dermoid tumor rupture was developed after car accident.^[13] In a recent case report, diagnoses of positive peritoneal lavage secondary to “simple” ovarian cyst rupture were defined which were also confirmed histopathologically in a 49-year-old postmenopausal woman who was passed over by a tractor wheel.^[14] In another article, an ovarian dermoid tumor case approximately 8 cm in diameter and had spontaneous rupture during labor was given.^[15] These findings show that severe blunt abdominal trauma and even labor may cause cyst ruptures. However, the case that abdominal examination even aggressively, or transvaginal probes may trigger rupture is only based on assumptions.

In our current case, it can be thought that cyst rupture appearing during sonographic examination is only a coincidence. We could not find any other case report which displayed ovarian cyst rupture by real-time ultrasonography despite comprehensive literature and internet search. Probably, detailed display of this case by Doppler technique has been recorded for the first time by us. During rupture, we found that fluid cyst content reaching high velocity enough to create aliasing was accumulated in posterior “cul-de-sac” also by the effect of gravity. This explains clinical picture appearing with abrupt pain in ovarian cyst ruptures.

Conclusion

Consequently, findings in the current case show that in the rupture of “simple” ovarian cysts, cyst fluid may flow into pelvic cavity in a short time and possible peritoneal irritation may cause abrupt and intense but temporary pain.

Conflicts of Interest: No conflicts declared.

References

1. Kupesić S, Aksamija A, Vucić N, Tripalo A, Kurjak A. Ultrasonography in acute pelvic pain. [Article in Croatian] *Acta Med Croatica* 2002;56:171-80.
2. Can M, Güney Ş, Öziz E. Transvajinal ultrasonografinin tanısal değeri. *İzmir Atatürk Eğitim ve Araştırma Hastanesi Tıp Dergisi* 1998;36:27-32.
3. Tanrıverdi HA, Sade H, Akbulut H, Barut V, Bayar Ü. Pelvik kitlelerin klinik ve ultrasonografik değerlendirmesi. *Journal of the Turkish German Gynecological Association* 2007;8:67-70.
4. Timor-Tritsch IE. Tubal ring and corpus luteum echogenicities. *J Ultrasound Med* 2001;20:802.
5. Bottomley C, Bourne T. Diagnosis and management of ovarian cyst accidents. *Best Pract Res Clin Obstet Gynaecol* 2009;23:711-24.
6. Dörum A, Blom GP, Ekerhovd E, Granberg S. Prevalence and histologic diagnosis of adnexal cysts in postmenopausal women: an autopsy study. *Am J Obstet Gynecol* 2005;192:48-54.
7. Borgfeldt C, Andolf E. Transvaginal sonographic ovarian findings in a random sample of women 25-40 years old. *Ultrasound Obstet Gynecol* 1999;13:345-50.
8. Haider Z, Condous G, Khalid A, Kirk E, Mukri F, Van Calster B, et al. Impact of the availability of sonography in the acute gynecology unit. *Ultrasound Obstet Gynecol* 2006;28:207-13.
9. Cicchiello LA, Hamper UM, Scoutt LM. Ultrasound evaluation of gynecologic causes of pelvic pain. *Obstet Gynecol Clin North Am* 2011;38:85-114.
10. Bourne TH, Hagström H, Hahlin M, Josefsson B, Granberg S, Hellberg P, et al. Ultrasound studies of vascular and morphological changes in the human corpus luteum during the menstrual cycle. *Fertil Steril* 1996;65:753-8.
11. Smeenk RM, Verwaal VJ, Zoetmulder FA. Pseudomyxoma peritonei. *Cancer Treat Rev* 2007;33:138-45.
12. Ignacio EA, Hill MC. Ultrasound of the acute female pelvis. *Ultrasound Q* 2003;19:86-98.
13. Levine RL, Pepe PE, Blackstone W, Danzinger J, Varon J. Occult traumatic avulsion of an ovarian dermoid cyst. *Am J Emerg Med* 1992;10:344-6.
14. Madej B, Fijalkowski P, Burdan F. Post-traumatic rupture of the ovarian cyst – case report. *Polski Przegląd Chirurgicalny* 2008;80:630-2.
15. Kumarie R, Machado LS, Krolikowski A. Spontaneous rupture of an ovarian tumor during labor. *Saudi Med J* 2002;23:350.