

Sequential therapy failure in a naturally conceived twin pregnancy complicated by reversed arterial perfusion

Ömer Yavuz Şimşek¹, Önder Çelik¹, Ercan Yılmaz¹, Ebru Çelik¹, Senem Arda Düz¹,
Serdar Ceylaner², Şevki Çelen³, Nuri Danişman³

¹Department of Obstetrics and Gynecology, Faculty of Medicine, İnönü University, Malatya, Turkey

²İntergen Genetic Diagnostic Center, Ankara, Turkey

³Dr. Zekai Tabir Burak Gynecology Training and Research Hospital, Ankara, Turkey

Abstract

Objective: Twin reversed arterial perfusion (TRAP) sequence is a rare complication of monochorionic multifetal gestation, and affects 1 of monochorionic twins. Here we present a case of acardiac twinning sequentially treated by laser umbilical insertion ablation and intrafetal alcohol injection.

Case: A 26-year-old woman admitted to our clinic in the 18th week of her pregnancy was presented. Ultrasonography showed a monochorionic twinning with a live pump fetus at and an acardiac cotwin. Although laser ablation and intraumbilical alcohol injection therapies were commenced with onemonth interval and blood flow of acardiac fetus was ceased, late demise of the pump twin was developed.

Conclusion: Although alcohol injection is a simple method in blood flow occlusion of acardiac fetus, this method should not be preferred as the first surgical intervention option due to risk of alcohol transfusion structurally passing to normal other twin.

Key words: Monochorionic twins pregnancy, fetal therapy, acardiac.

Akardiyak ikizlikle komplike olmuş spontan monokoryonik ikiz gebelikte ardışık tedavi başarısızlığı

Amaç: Akardiyak ikizlik ya da ikiz ters arteriyel perfüzyon (TRAP), monokoryonik çoğul gebeliklerin nadir bir komplikasyonudur ve monokoryonik ikizlerin birini etkiler. Bu yazıda sırasıyla lazer ablasyon ve intrafetal alkol enjeksiyonu uygulanan bir akardiyak ikiz gebelik sunulmuştur.

Olgu: Kliniğimize gebeliğin 18. gebelik haftasında başvuran 26 yaşında bir hasta tartışıldı. Ultrasonografide bir canlı verici fetus ve akardiyak ikiz eşi olan monokoryonik ikiz gebelik saptandı. Bir aylık ara ile lazer ablasyon ve intraumbilikal alkol enjeksiyonu uygulanmasına ve akardiyak fetüsün kan akımı durdurulmasına karşın ilerleyen haftalarda verici ikiz kaybedildi.

Sonuç: Akardiyak fetüsün kan akımının oklüzyonunda alkol enjeksiyonu basit bir yöntem olmasına rağmen bu yöntem alkol transfüzyonunun yapısal olarak normal ikiz eşine geçmesi riski nedeniyle ilk cerrahi müdahale tercihi olarak seçilmemelidir.

Anahtar sözcükler: Monokoryonik ikiz gebelik, fetal tedavi, akardiyak.

Introduction

Acardiac or twin reversed-arterial-perfusion (TRAP) sequence is a rare but serious malformation that occurs in one of monozygotic twins, triplets, or even quintuplets with a frequency of approximately 1 per 35,000

deliveries.^[1] TRAP sequence occurs only in the setting of a monochorionic gestation and complicates approximately 1% of monochorionic twin gestations.^[2] In the TRAP sequence, there is usually a normally formed pump twin who has features of heart failure as well as a

Correspondence: Ömer Yavuz Şimşek, MD. İnönü Üniversitesi Tıp Fakültesi, Kadın Hastalıkları ve Doğum Anabilim Dalı, Malatya, Turkey.
e-mail: dryavuzsimsek@yahoo.co.uk

Received: September 21, 2011; **Accepted:** December 20, 2011



recipient twin who lacks a heart (acardiac monster) and perfused from pump co-twin through vascular (almost always arterial–arterial and venous–venous) anastomoses. This deoxygenized arterial blood reaches the recipient twin through its umbilical arteries and preferentially goes to its iliac vessels. Thus, only the lower body is perfused, and this is usually associated with poor or absent development of the heart and upper part of the body. Antenatal diagnosis by ultrasound of an acardiac fetus coexisting with a normal co-twin is fairly straight-forward. The anomalous twin may appear to be an amorphous mass. The lower extremities and body are typically more completely developed, while the most severe abnormalities involve the upper body. The heart is frequently absent or rudimentary, and a single umbilical artery is present in approximately half the cases. A retrograde pattern of fetal perfusion can be demonstrated to occur through the umbilical arteries by Doppler studies.^[3–5] If left untreated, the pump twin dies in 50% to 75% of cases, mainly as a result of polyhydramnios, preterm labor, and congestive heart failure.^[2–4] Interruption of the vascular communication between the twins has been recommended to improve perinatal outcome of the pump twin. Here, we report a case of acardiac twin pregnancy result with the late demise of the pump twin after the sequential surgical intervention performed with an interval of one month.

Case Report

26-year-old, gravidy 4, parity 3 patient at 18 weeks of gestation admitted to our high risk pregnancy department as a case of acardiac twin pregnancy. Of note in her medical and obstetric history was unremarkable. Ultrasonography showed a monochorionic twin pregnancy with a live pump fetus at 18 weeks of gestation and an acardiac co-twin and polyhydramnios (**Fig. 1**) (acardius acephalus type). A thin, complete membrane was present between the 2 sacs of gestation. The pump twin was in a breech presentation, with normal fetal anatomy, while the acardiac twin had grossly abnormal anatomy. There were an amorph view in the thorax, no identifiable heart structures and no definition of the fetal skull above the thorax. Estimated fetal weight was 226 g for the pump twin and 200 g for the recipient twin. On pulsed Doppler examination, the direction of blood flow in the umbilical arteries of acardiac twin was in the opposite direction, but the hemodynamics in pump twin were normal. After the diagnosis was confirmed, patient was informed about the poor prognosis of her pregnancy. After a discussion with the patient, she was referred to a tertiary perinatal center for laser ablation of communicating vessels between the pump and acardiac fetuses. The ablation procedure was performed at 22th week of gestation. However, unceased circulation in acardiac fetus was noticed during the follow up of the patient and diagnosis of unsuccessful laser

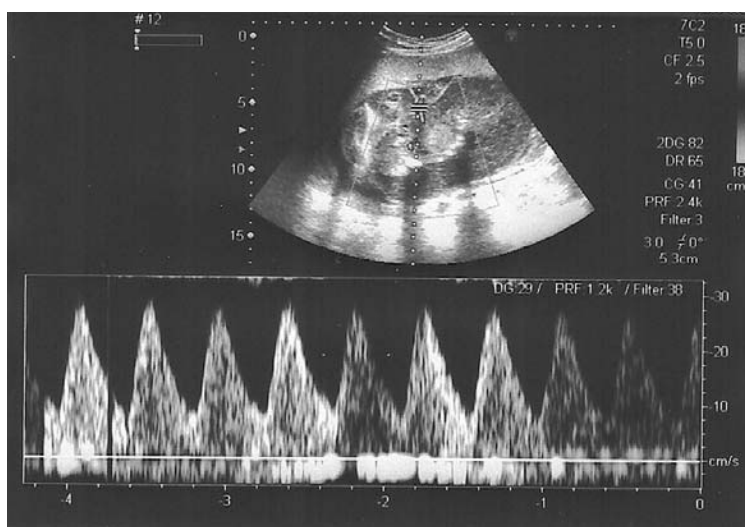


Fig. 1. Blood flow of the acardiac twin on Doppler ultrasonography at 18 weeks of gestation.

ablation therapy was made. The family was informed and a written informed consent was obtained from both parents for intra-fetal alcohol injection therapy. The procedure was performed under continuous ultrasound control, using color Doppler ultrasound to identify the main arterial vessel entering the abdomen of the acardiac twin and passing a 20-gauge spinal needle into the targeted vessel. After blood sampling for karyotyping, intra-fetal injection of 2.0 ml of absolute alcohol to the main intra-abdominal segment of the single umbilical artery was performed to the acardiac twin at 23th week of gestation and the circulation was ceased (**Fig. 2**). Early postoperative period was uneventful. Analysis of fetal blood showed a normal 46 XY male karyotype. Follow-up of the living fetus was unremarkable until the 27th week of gestation, in which the sudden death of the pump twin was diagnosed sonographically. Pregnancy was terminated by vaginal misoprostol induction with a total dose of 800 µg in two divided doses. A male ex pump fetus 625 g in weigh, a male acardiac fetus 325 g in weigh and a single hydropic placenta 389 g in weigh were delivered via vaginal route. The pump fetus had no obvious congenital malformation. The upper portion of the acardiac twin contained soft globular masses. The head and upper extremities were absent (**Fig. 3**). The right foot had 5 toes and the left foot had 3 toes. The lower spinal column and lower extremity bones were apparently normal. Samples were taken from both twins for genetic analysis and each twin

were sent for an autopsy. Autopsy of the acardiac twin revealed absent thoracic organs, a bony ridge representing the lower part of the spine, bilateral kidneys, bilateral surrenal glands and a small part of large intestines. Autopsy of the pump twin showed a phenotypically normal male fetus. Karyotyping of the pump twin was revealed normal male 46 XY karyotype. Histopathology of the placenta was suggestive of monochorionic-diamniotic twin pregnancy. Postpartum follow-up of the patient was unremarkable.

Discussion

The goal of antepartum management of a twin pregnancy complicated by the TRAP sequence is to maximize for the structurally normal pump twin. Because of the increased demand that the abnormal circulation in TRAP sequence places on the heart of the pump twin, cardiac failure is the primary concern in the condition. Various techniques have been described to accomplish the blocking of arterial perfusion of acardiac twin. These methods have included hysterotomy with physical removal of the acardiac twin, bipolar coagulation, laser ablation, radiofrequency ablation, ultrasound-guided injection of thrombogenic materials into the umbilical circulation of the acardiac twin, and laser occlusion of the placental vascular anastomosis under fetoscopic guidance.^[5-8] On the other hand, Malone et al. have suggested that expectant management with

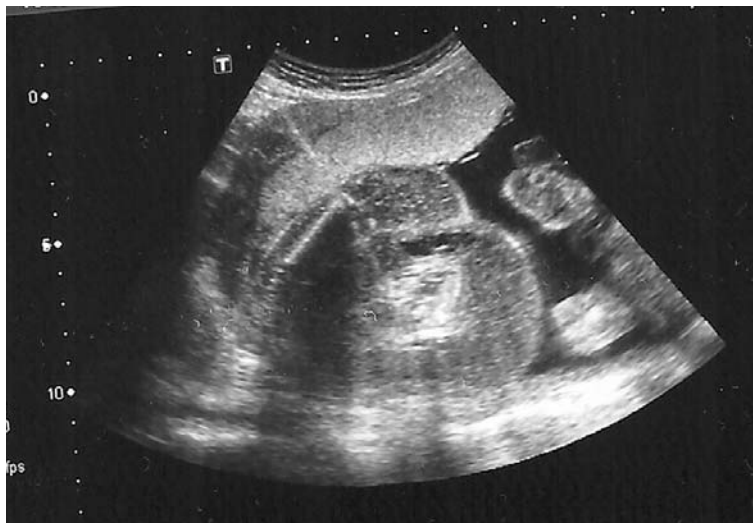

Fig. 2. Intrafetal alcohol injection procedure under the guidance of color Doppler ultrasonography

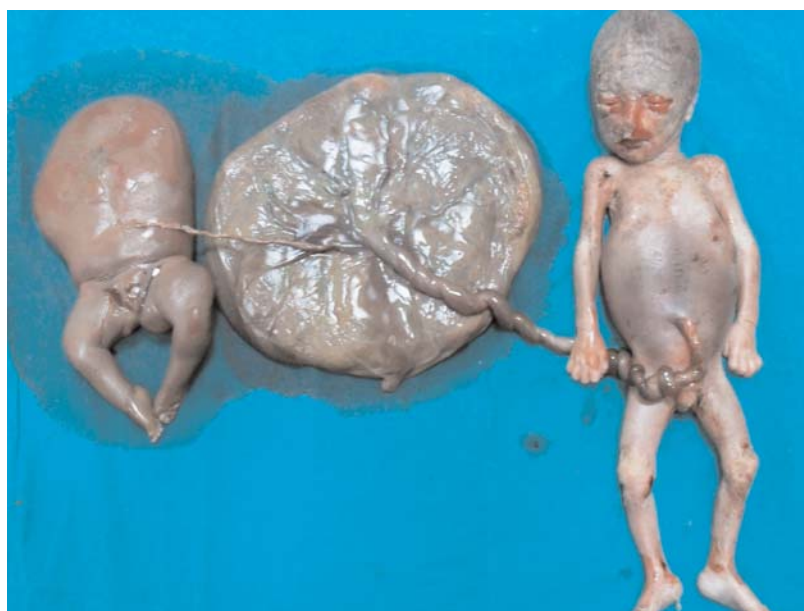

Fig. 3. The acardiac twin, pump twin and monochorionic diamniotic placenta. [Color figure can be viewed in the online issue, which is available at www.perinataljournal.com]

serial ultrasonographic evaluation is reasonable in the absence of poor prognostic features (twin weight ratio >0.70 , elevated ventricular out-put of pump twin, increased cardio-thoracic ratio, congestive heart failure, rapid growth of the pump twin and polyhydramnios).^[7] In the present case, the twin weight ratio was 0.88 and polyhydramnios was diagnosed by antenatal sonography. Surgical treatment was decided after a discussion with the patient about the expected poor perinatal outcome of the current pregnancy. The difference in estimated fetal weight between the pump twin and the acardiac/acephalic twin has been suggested the main predictive determinant of the perinatal outcome in cases with TRAP sequence. In the series of 49 cases reported by Moore et al., the mean overall ratio of the twin weights was found to be $52 \pm 24\%$.^[4] When the ratio was more than 70%, the incidence of preterm delivery was 90% and congestive heart failure in the pump twin 30%, as compared with 75% and 10%, respectively. The overall perinatal mortality was 55% and was primarily associated with prematurity. Sullivan et al., however reported 10% perinatal mortality rate of the cases with TRAP sequence. They cautioned against aggressive surgical intervention and recommended conservative management although weight ratio of acardiac to pump twin was less than 5% in 40%

of the cases in their series.^[8] The optimal surgical treatment of the TRAP sequence is currently unknown, due to the limited number of cases and lack of the comparative studies. Fetoscopic cord ligation is only available in few centers around the world, requires expensive settings and skilled operators, and it is associated with a failure rate of 10% together with a 30% risk of preterm premature rupture of membranes.^[9] Ultrasound guided needling techniques on the other hand, can be carried out in any center with the facilities to perform fetal blood sampling, requires simple instruments and low-cost material, and is less traumatic to the uterus and membranes. The intrafetal injection of alcohol for the treatment of acardiac twins was first reported by Holzgreve et al.^[5] Subsequently, Sepulveda et al. presented the largest series reporting the results of intrafetal alcohol chemo sclerosis in the treatment of acardiac twin pregnancies.^[10] In their series, the procedure was performed at a mean gestational age of 24.7 weeks (range 20–32), and it was technically successful in all cases. They reported the 63% of overall survival rate without any neonatal complications. However, it was complicated with thrombosis of the umbilical vessels of the pump twin in 3 case and all of these 3 pump twins died in utero as a result of the procedure (36%). In the present case, the patient was

referred a tertiary perinatal center in order to obliterate of blood perfusion by the acardiac twin. The laser ablation was performed, however the intervention was unsuccessful and unceased circulation of acardiac twin was diagnosed during the follow-up of the patient. One month later a new intervention was commenced with the injection of absolute alcohol which was successful without technical difficulty. Late demise of the pump twin in the present case was not considered to be linked to the alcohol chemosclerosis procedure. Although, intrafetal alcohol chemosclerosis is a simple and cost-saving procedure that can be performed in any perinatal center, the major concern with this technique is intravascular transfer of the absolute alcohol to the circulation of the pump twin. On account of this, the use of this technique should not be considered as a first line therapy in pregnancies with poor prognostic factors.

Conclusion

The TRAP sequence in monochorionic twin gestations is a rare complication that compromises the viability of the morphologically normal, pump twin. The clinical dilemma regarding the decision to intervene is currently unclear and a step by step treatment algorithm is not available. In this report, we present a case of acardiac twinning primarily treated with laser ablation and then intra-fetal alcohol injection with an interval of one month. Although, the alcohol injection is a simple way to occlude the blood supply of the acardiac fetus as in the presented case, the method should not be considered as a first line surgical option because of comparable risk of the transfusion risk of alcohol to the structurally normal twin.

Conflicts of Interest: No conflicts declared.

References

1. Sogaard K, Skibsted L, Brocks V. Acardiac twins: pathophysiology, diagnosis, outcome, and treatment. Six cases and review of the literature. *Fetal Diagn Ther* 1999;14:53-9.
2. Van Allen MI, Smith DW, Shepard TH. Twin reversed arterial perfusion (TRAP) sequence: a study of 14 twin pregnancies with acardius. *Semin Perinatol* 1983;7:285-93.
3. Jelin E, Hirose S, Rand L, Curran P, Feldstein V, Guevara-Gallardo S, et al. Perinatal outcome of conservative management versus fetal intervention for twin reversed arterial perfusion sequence with a small acardiac twin. *Fetal Diagn Ther* 2010;27:138-41.
4. Moore TR, Gale S, Benirschke K. Perinatal outcome of forty-nine pregnancies complicated by acardiac twinning. *Am J Obstet Gynecol* 1990;163:907-12.
5. Holzgreve W, Tercanli S, Krings W, Schuierer G. A simpler technique for umbilical-cord blockade of an acardiac twin. *N Engl J Med* 1994;331:56-7.
6. Porreco RP, Barton SM, Haverkamp AD. Occlusion of umbilical artery in acardiac, acephalic twin. *Lancet* 1991;337:326-7.
7. Malone FD, D'Alton ME. Anomalies peculiar to multiple gestations. *Clin Perinatol* 2000; 27:1033-46.
8. Sullivan AE, Varner MW, Ball RH, Jackson M, Silver RM. The management of acardiac twins: a conservative approach. *Am J Obstet Gynecol* 2003;189:1310-3.
9. Quintero RA, Reich H, Puder KS, Bardicef M, Evans MI, Cotton DB, et al. Brief report: umbilical-cord ligation of an acardiac twin by fetoscopy at 19 weeks of gestation. *N Engl J Med* 1994;330:469-71.
10. Sepulveda W, Corral E, Aiello H, Otaño L, Paredes R, Escobar MF, et al. Intrafetal alcohol chemosclerosis of acardiac twins: a multicenter experience. *Fetal Diagn Ther* 2004;19:448-52.