

Prenatal Diagnosis of Omphalocele and Beckwith-Wiedemann Syndrome: a Case Report

Sema Tanrıverdi¹, Rengin Ayçiçek¹, Onur Bağcı¹, Bertan Karaboğa², Aydın Şencan³, Faik Mümtaz Koyuncu⁴

¹Celal Bayar Üniversitesi Tıp Fakültesi, Çocuk Sağlığı ve Hastalıkları Anabilim Dalı, Neonatoloji Bilim Dalı, Manisa, Türkiye

²Celal Bayar Üniversitesi Tıp Fakültesi, Çocuk Sağlığı ve Hastalıkları Anabilim Dalı, Manisa, Türkiye

³Celal Bayar Üniversitesi Tıp Fakültesi, Çocuk Cerrahisi Anabilim Dalı, Manisa, Türkiye

⁴Celal Bayar Üniversitesi Tıp Fakültesi, Kadın Hastalıkları ve Doğum Anabilim Dalı, Manisa, Türkiye

Abstract

Objective: We report a case with the diagnosis of omphalocele antenatally but additionally Beckwith-Wiedemann Syndrome neonatally.

Case: The case, which omphalocele was determined at 28th week of gestation prenatally, was delivered with cesarean section at 39th week. The case was operated immediately after birth. The case was assessed as Beckwith-Wiedemann Syndrome with clinical manifestations which were omphalocele, macroglossia and macrosomy at birth.

Conclusion: When anterior abdominal wall defect is determined such as omphalocele at prenatal or postnatal period, congenital malformations are considered which accompany omphalocele such as BWS and a detailed physical examination must be performed.

Keywords: Beckwith-Wiedemann syndrome, omphalocele, macroglossia, newborn.

Prenatal tanımlı omfalosel ve Beckwith-Wiedemann sendromu: Olgu sunumu

Amaç: Prenatal USG ile omfalosel saptanan ve doğumdan sonra Beckwith-Wiedemann sendromu saptanan bir olguyu literatür eşliğinde sunulmaktadır.

Olgu: Prenatal 28. haftada yapılan ultrasonografi ile omfalosel tanısı alan hasta 39. gebelik haftasında sezaryen ile doğurtuldu ve olgu doğumdan hemen sonra opere edildi. Omfalosel, makroglosi ve makrozomi ile kendini gösteren Beckwith-Wiedemann Sendromu olarak tanısı konuldu.

Sonuç: Prenatal veya postnatal omfalosel gibi karın ön duvarı defekti olan olguların omfalosele eşlik edebilecek konjenital anomaliler açısından özellikle de BWS açısından dikkatli olunmalı ve iyi bir fizik muayene yapılması gerekmektedir.

Anahtar Sözcükler: Beckwith-Wiedemann sendromu, omfalosel, makroglossi, yenidoğan.

Introduction

Prenatal sonography provides the possibility to detect the majority of abdominal wall defects. Omphalocele and gastroschisis are the most common types. Omphalocele is a midline abdominal wall defect with extrusion of abdominal viscera, covered by a membranous sac, into the base of the umbilical cord and is the one of the most common congenital malformation of the anterior abdominal

wall.^[1,2] Omphalocele is frequently associated with other congenital malformations. However, the frequency of the reported associated malformations for omphalocele ranges from 27% to 63%. Beckwith-Wiedemann Syndrome (BWS) is a congenital malformation which is associated with omphalocele.^[2-4]

BWS is a rare congenital overgrowth condition characterized by pediatric features of macroglossia, gigantism, omphalocele, visceromegaly, hemihy-

perplasia, seizures (when there is neonatal hypoglycemia), renal malformations, prominent facial nevus flammeus, ear lob anomalies.^[5,6] It affects approximately 1 in 14,000 births.^[5] Female and male ratio is similar. This syndrome can be sporadic (85%) or inherited (15%).^[7,8]

BWS was described independently by two investigators. In 1963, Beckwith presented three postmortem cases with macroglossia, omphalocele, cytomegaly of the fetal adrenal cortex, renal medullary dysplasia and visceromegaly. On the other hand, Wiedemann in 1964 reported three cases of siblings with similar clinical characteristics, adding diaphragm defects and hypoglycemia.^[9]

Macroglossia, defects of the abdominal wall and macrosomy are three major features of BWS. Macroglossia is the most common feature in this syndrome.^[7,8] Almost all known cases of BWS are diagnosed after birth on the basis of physical examination features.^[10,11] We reported a case with BWS which was characterized with macroglossia, macrosomia, ear lobe creases, omphalocele which was diagnosed prenatal sonography and performed immediate surgical treatment to her.

Case Report

The case, which omphalocele was determined at 28th week of gestation prenatally, was delivered with cesarean section at 39th week by 21 years old

gravida 1, para 0 mother (Figures 1-3). The case was operated immediately after birth (Figure 4).

The baby's weight was 4160 g (75th-90th p), height was 52 cm (75th-90th p) and head circumference was 36 cm (50th-75th p). Cardiac pulse, respiration rate and blood pressure of baby were normal. Omphalocele was determined. There was anterior abdominal defect with bowel in the sac that covered by a transparent membranous and umbilical cord at the top of the sac. Also macroglossia, grooves in the ear lobe and macrosomia were determined. The other physical examinations were normal (Figures 4-6).

WBC was 12,600/mm³, hemoglobin was 18.8 g/dl, hematocrit was 53.1% and platelet was 205,000/mm³ at CBC. Na was 129 mmol/L, K was 4.1 mmol/L, Cl, Ca, P04, AST, ALT, urea, creatinine and blood sugar were normal. The omphalocele sac was covered with sterile wet pads for preventing heat and fluid loss until operation. Also incubator temperature was increased. Blood glucose levels of baby were monitored. The levels were normal. Abdominal organs of baby were placed into the abdominal cavity and abdominal wall was closed after 4 hours from birth.

The case was assessed as BWS with clinical manifestations which were omphalocele, macroglossia and macrosomy at birth. Abdominal ultrasound was normal. There were not any organomegaly or renal anomalies. Also echocar-

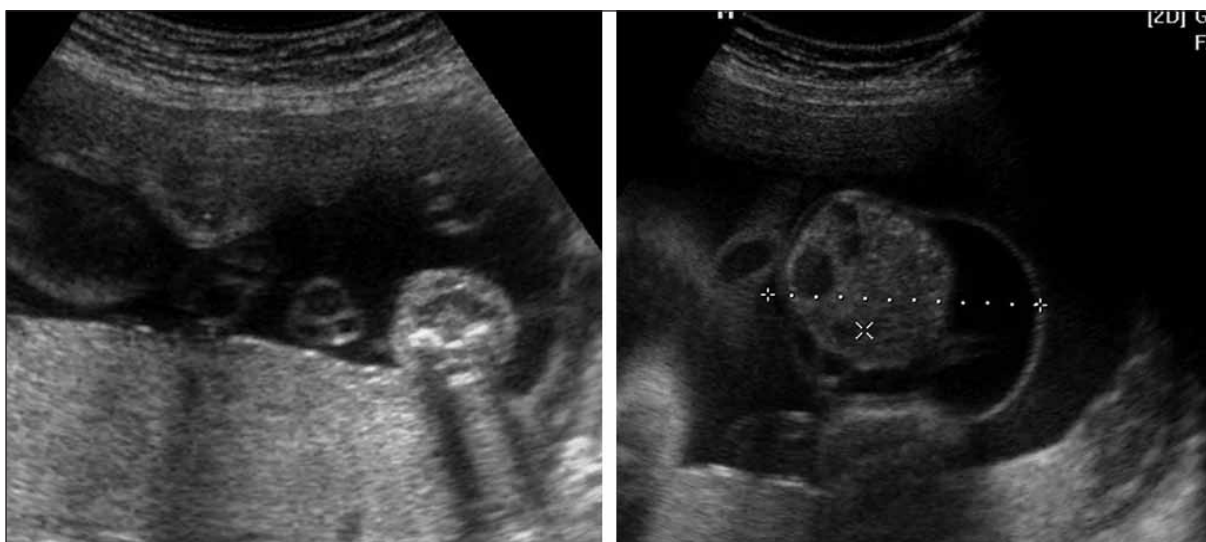


Figure 1. Omphalocele. Prenatal ultrasound appearance.

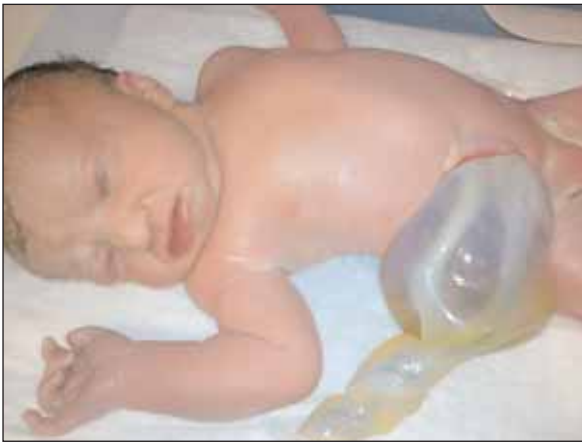

Figure 2. Omphalocele. Pre-operative view.

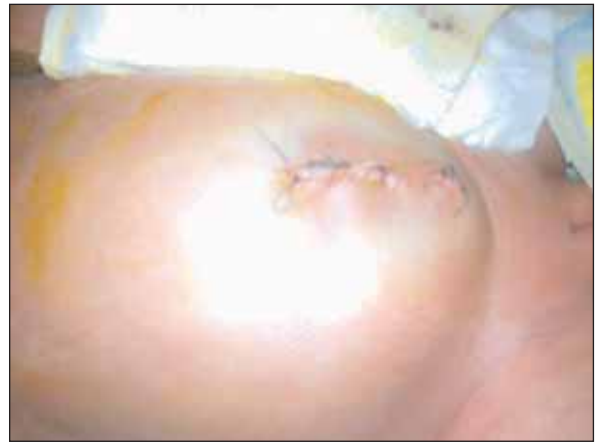

Figure 3. Omphalocele. Post-operative view.

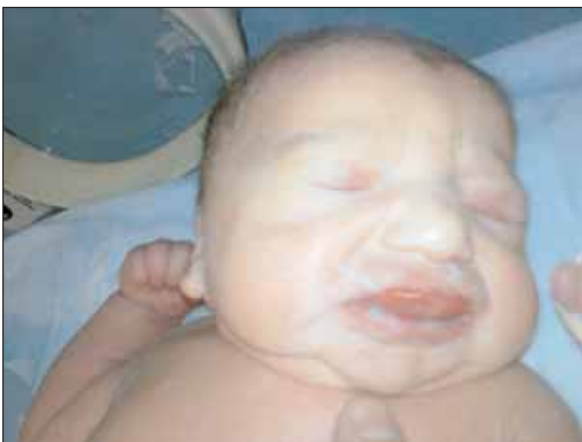

Figure 4. Macroglossia.

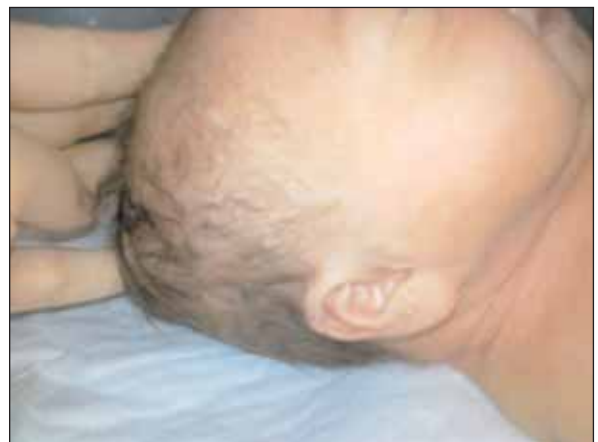

Figure 5. Ear lobe anomaly.

diography was normal. The case is been following for development of embryonal malignancies.

Discussion

Omphalocele is one of the most common congenital malformations of the anterior abdominal wall. Although volume of the intraabdominal is low, folds of the intraabdominal are developed normally. The abdominal organs with surrounding amniotic sac are outside the abdominal cavity. Umbilical cord is in the amniotic sac and creates the top of the sac. Liver, spleen and all organs of the gastrointestinal tract may take place in the omphalocele sac. Prenatal sonography provides the possibility to detect the majority of abdominal wall defects.^[1,2] Omphalocele was detected at 28th weeks of gestation by prenatal ultrasound at our case.

Omphalocele is frequently associated with other congenital malformations. However, the frequency of the reported associated malformations for omphalocele ranges from 27% to 63%.^[2,3] Cardiac anomalies are seen at a rate of 15-25%.^[2,3] BWS is a congenital malformation which is associated with omphalocele.

Previous reports have shown that the prenatal diagnosis of BWS may be suggested by ultrasound. Characteristic findings that may be detected with prenatal sonography include macrosomia, macroglossia, omphalocele, polyhydramnios, hepatomegaly, and renal enlargement. Down syndrome, trisomy 18 and other overgrowth conditions such as Sotos' syndrome, Weaver syndrome and Marshall-Smith syndrome, may have similar prenatal ultrasound findings. Compared with BWS, these

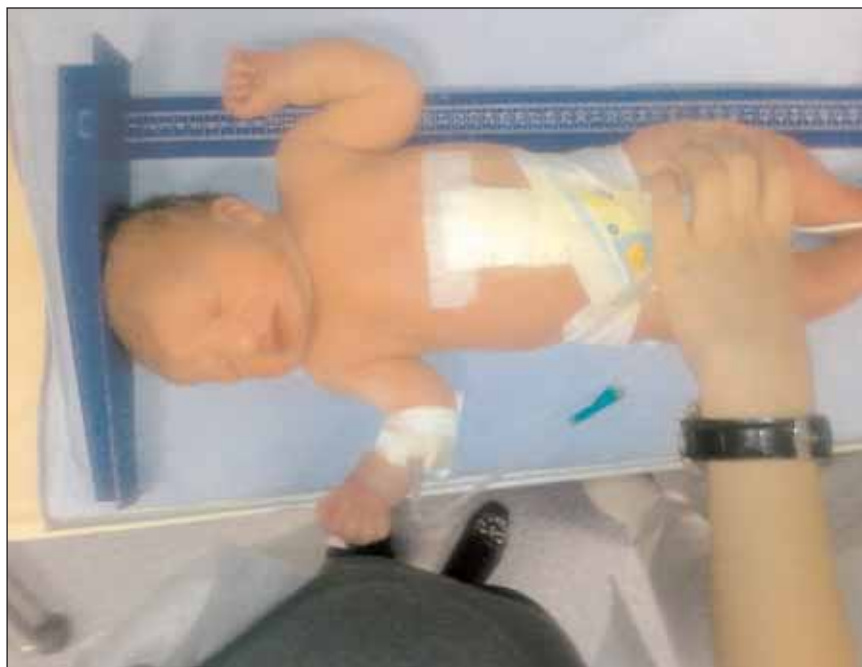

Figure 6. Macrosomia.

other overgrowth conditions are usually not associated with visceromegaly, macroglossia or omphalocele.^[6] In our case, there were no other findings except of omphalocele at ultrasound in prenatal period and BWS was diagnosed with physical examination findings in the postnatal period.

BWS is a rare congenital overgrowth condition characterized by pediatric features of macroglossia, gigantism, omphalocele, visceromegaly, hemihyperplasia, seizures (when there is neonatal hypoglycemia), renal malformations, prominent facial nevus flammeus, ear lob anomalies.^[5,6] Almost all known cases of BWS are diagnosed after birth on the basis of physical exam features. While there are no fixed diagnostic criteria for BWS and no one feature is obligatory in making the diagnosis, postnatal definitions include either three major features (Anterior abdominal wall defect, macroglossia, pre- or postnatal overgrowth) or two major features plus three minor features (ear creases on the lobes or post-auricular pits, prominent facial nevus flammeus, hypoglycemia, nephromegaly, or hemihyperplasia).^[6,10,11] Clinically, it presents in diverse forms, its most common features being macroglossia (97-100%) which can be asymmetric, defects of the abdominal wall (77-80%), hypoglycemia (63%) and macrosomy (68%).^[7,8,12,13] Some of these features such as nephromegaly and other findings like

polyhydramnios can be detected prenatally; however, others are not found until after birth.^[6,14] In our case BWS was diagnosed with three major diagnostic criteria such as omphalocele, macroglossia and macrosomia. Minor features of the syndrome such as visceromegaly, renal malformations (renal medullary dysplasia, fetal lobulation, nephromegaly, renal cysts) were not in our case. Hypoglycemia was not detected at the case. Echocardiography was normal.

This genetic syndrome has its apparent origin in an alteration of the expression of genes from the chromosome 11 region p 15.5, which can be sporadic (85%), inherited (15%). This alteration has been found primarily on the insulin growth factor 2 genes which is a fetal growth factor.^[7,8,13] BWS involves dysregulation of imprinted growth regulation of imprinted growth regulatory genes on chromosome 11p15.5. Female and male are similar to the incidence of BWS.^[7,8,13] Similar clinical findings of BWS were not in our case's family so that we were considered our case as sporadic BWS. Genetic counseling was given to family.

Our case's omphalocele was detected at prenatal period and was operated immediately after. The defects of the anterior abdominal wall must be treated immediately from birth.^[15]

Early diagnosis of BWS is particularly important because of the well documented increase in risk for development of embryonal malignancies, most commonly Wilms tumor and hepatoblastoma but also a variety of other tumors, both benign and malignant including neuroblastoma, rhabdomyosarcoma, and adrenocortical carcinoma. This risk is approximately 7.5%; tumors present primarily in the first 8 years of life.^[16,17] At present, this strategy includes abdominal ultrasound every 3 months to the age of 8 years and alpha fetoprotein assay every 3 months to the age of 4 years.^[18-20] Our case is being followed for development of malignancies.

Conclusion

When anterior abdominal wall defect is determined such as omphalocele at prenatal or postnatal period, congenital malformations are considered which accompany omphalocele such as BWS and a detailed physical examination must be performed.

References

- Moore TC, Stokes GE. Gastroschisis; report of two cases treated by a modification of the gross operation for omphalocele. *Surgery* 1953;33:112-20.
- Stoll C, Alembik Y, Dott B, Roth M-P. Omphalocele and gastroschisis and associated malformations. *Am J Med Genet Part A* 2008;146A:1280-85.
- Fisher R, Attah A, Partington A, Dykes E. Impact of antenatal diagnosis on incidence and prognosis in abdominal wall defects. *J Pediatr Surg* 1996;31:538-41.
- Stepan H, Horn L C, Bennek J, Faber R. Congenital hernia of the abdominal wall: a differential diagnosis of fetal abdominal wall defects. *Ultrasound Obstet Gynecol* 1999;13:207-9.
- Harker CP, Winter T 3rd, Mack L. Prenatal diagnosis of Beckwith-Wiedemann syndrome. *AJR Am J Roentgenol* 1997;168:520-22.
- Williams DH, Gauthier DW, Maizels M. Prenatal diagnosis of Beckwith-Wiedemann syndrome. *Prenat Diagn* 2005;25:879-84.
- Reish O, Lerer I, Amiel A, Heyman E, Herman A, Dolfin T, et al. Wiedemann-Beckwith syndrome: further prenatal characterizations of the condition. *Am J Med Genet* 2002;107:209-13.
- Li M. Molecular genetics of Wiedemann-Beckwith syndrome (BWS) a case report and literature review. *Am J Med Gen* 1998;79:253-9.
- Wiedemann HR. Familial malformation complex with umbilical hernia and macroglossia-a 'new syndrome'? *J Genet Hum* 1964;13:223-32.
- Elliott M, Maher ER. Beckwith-Wiedemann syndrome. *J Med Genet* 1994;31:560-4.
- Çakmak A, Karazeybek AH. Beckwith-Wiedemann syndrome: case report. *Türkiye Klinikleri J Pediatr* 2007; 16:58-61.
- Chang AS, Moley KH, Wangler M, Feinberg AP, Debaun MR. Association between Beckwith-Wiedemann and assisted reproductive technology: a case series of 19 patients. *Fertil Steril* 2005;83:349-54.
- Narea Matamala G, Fernández Toro Mde L, Villalabeitia Ugarte E, Landaeta Mendoza M. Beckwith Wiedeman syndrome: presentation of a case report. *Med Oral Patol Oral Cir Bucal* 2008;13:640-3.
- Williams DH, Gauthier DW, Maizels M. Prenatal diagnosis of Beckwith-Wiedemann syndrome. *Prenat Diagn* 2005;25:879-84.
- Solsona-Narbón B, Castillo Laita JA, Buñuel Alvarez JC, Elías Pollina J, Loris Pablo C, et al. Beckwith-Wiedemann syndrome: study of eleven cases. *An Esp Pediatr* 1992;36:181-5.
- Tan TY, Amor DJ. Tumour surveillance in Beckwith-Wiedemann syndrome and hemihyperplasia: a critical review of the evidence and suggested guidelines for local practice. *J Paediatr Child Health* 2006;42:486-90.
- Aka S, Derbent M, Sarılioğlu F. Beckwith-Wiedemann sendromu ve hepatoblastoma. *Türkiye Klinikleri J Pediatr* 2010;19:359-63.
- Debaun MR, Tucker MA. Risk of cancer during the first four years of life in children from the Beckwith-Wiedemann syndrome registry. *J Pediatr* 1998;132:398-400.
- Evermann DB, Shuman C, Dzolganovski B, O'riordan MA, Weksberg R, Robin NH. Serum alpha-fetoprotein levels in Beckwith-Wiedemann syndrome. *J Pediatr* 2000;137:123-7.
- Zarate YA, Mena R, Martin LJ, Steele P, Tinkle BT, Hopkin RJ. Experience with hemihyperplasia and Beckwith-Wiedemann syndrome surveillance protocol. *Am J Med Genet Part A* 2009;149A:1691-97.