

# An Anaplastic Astrocytoma Which is Diagnosed in Pregnancy: A Case Report

Orkun Çetin<sup>1</sup>, Seyfettin Uludağ<sup>1</sup>, Begüm Aydoğan<sup>1</sup>, Cihat Şen<sup>1</sup>, İpek Çetin<sup>2</sup>

<sup>1</sup>I.Ü. Cerrahpaşa Tıp Fakültesi, Kadın Hastalıkları ve Doğum Anabilim Dalı, İstanbul, TR

<sup>2</sup>I.Ü. Cerrahpaşa Tıp Fakültesi, Çocuk Sağlığı ve Hastalıkları Anabilim Dalı, İstanbul, TR

## Abstract

**Objective:** Astrocytoma, central nervous system called astrocytes small, star shaped glial cells, glialderived and the most common malignant tumors. We discussed the management of anaplastic astrocytoma, which was first diagnosed in the 26th gestational week, in the highlights of the literature.

**Case:** 28 year old patient, in 26th gestational week was admitted to our hospital with persistent headache, numbness in the left side of the body and neck swelling. As a result of Magnetic Resonance Imaging, a cranial tumor located in the anterior of the medulla oblongata was diagnosed. In 27th gestation week, extramedüller cervical intradural tumor excision was performed. The patient was delivered by cesarean section in 34th gestational week. After cesarean section, radiotherapy treatment was started.

**Conclusion:** Patients with anaplastic astrocytoma are rare in pregnancy. To help the management of this patients, new, largescale case series are needed. For the best obstetric and neurological results, treatment is carried out in tertiary centers with multidisciplinary approach.

**Keywords:** Anaplastic astrocytoma, pregnancy, multidisciplinary approach.

## Gebelikte tanı alan anaplastik astrositoma: olgu sunumu

**Amaç:** Astrositomlar, merkezi sinir sistemindeki astrosit adı verilen küçük, yıldız şeklindeki glial hücrelerden köken alan kötü huylu ve en sık görülen glial tümörlerdir. 26. gebelik haftasında tanısı konulan maternal anaplastik astrositoma olgusunun takip ve yönetimini literatür bilgileri ışığında tartıştık.

**Olgu:** 28 yaşında hasta, 26. gebelik haftasında persiste eden baş ağrısı, sol kolunda ve bacağında uyuşma, boyunda şişlik şikayetleri ile kliniğimize başvurdu. Manyetik Rezonans görüntüleme sonucunda hastaya, medulla oblongata yerleşimli kranial tümör ön tanısı konuldu. Hastaya, 27. gebelik haftasında servikal intradural extramedüller tümör eksizyonu yapıldı. Hasta, 34. gebelik haftasında sezaryen ile doğurtuldu. Sezaryen sonrasında radyoterapi tedavisine başlandı.

**Sonuç:** Gebelikte nadir görülen anaplastik astrositoma olgularının yönetiminde yardımcı olacak, yeni, geniş ölçekli olgu serilerine ihtiyaç vardır. En iyi obstetrik ve nörolojik sonuçları elde etmek için tedavi, tersiyer merkezlerde ve multidisipliner yaklaşımla gerçekleştirilmelidir.

**Anahtar Sözcükler:** Anaplastik astrositoma, gebelik, multidisipliner yaklaşım.

## Introduction

Astrocytomas are the most common malignant glial tumors originated from small star shaped glial cells called astrocytes within central nervous system. Anaplastic astrocytomas (AA) are defined as grade 3 glial tumors accord-

ing to the classification made by WHO in 2000. While the incidences of multi-formed glioblastoma and anaplastic astrocytoma were 0.2-0.5 in 100,000 for those 14 years old, it is 4-5 in 100,000 for those over 45 years old. The localization of anaplastic astrocytomas varies

according to age. While most of them locate at cerebellum below 25 years old, it is frequently located at cerebral over 25 years old.<sup>1</sup>

AA generally appears sporadically without any definable environmental factor or any genetic familiarity. AA is more frequent in women than men. At the same time, it is more frequent in white race than black race.

In AA, symptoms of clinical classical intracranial pressure increase (headache, vomit, conscious disorders, 3rd and 6th cranial nerve involvements) are frequently observed as in other intracerebral lesions. High phased astrocytic tumors do not cause hydrocephaly since they generally do not locate at ventricle. Neurological deficits appear depending on the location zones. Appearance of epileptic findings due to irritative effect is frequent in frontal and temporal located tumors. Classically, headache, epileptic seizure and hemiparesis triad are seen more than half of the cases.<sup>2</sup> Although primary intracranial tumors are rarely seen in women between 20 and 39 years old, it is at the fifth rank among cancer-related deaths.<sup>3</sup> While glial tumors are the most frequent tumor types among this age group, followed by meningiomas and acoustic neurinomas.<sup>4</sup> When women who are pregnant and who are not pregnant at same ages, no difference was found among primary brain tumor incidence.<sup>5</sup>

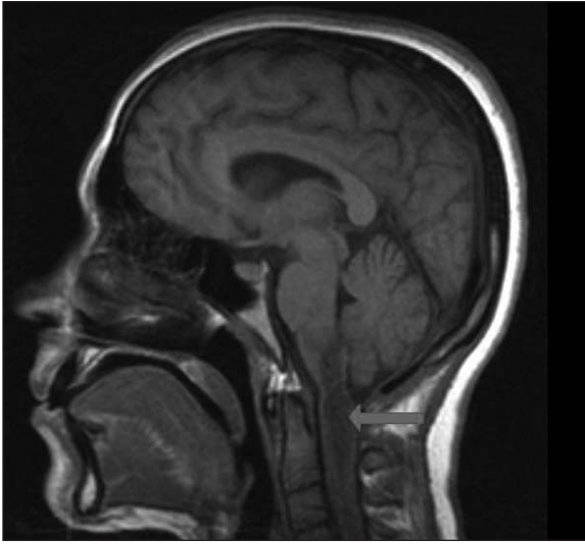
Standard treatments of AA are surgical and postoperative radiotherapies. High dose of radiotherapy, adjuvant chemotherapy, alternative fraction regimes, heavy particle treatment, interstitial brachytherapy and radiosurgery are used as different treatment modalities in order to elongate survival period.<sup>12</sup> However, a consensus have not been reached as there is no data except case series within the literature about the patient management during pregnancy.

In our case, we discussed the follow-up and management of maternal anaplastic astrocytoma diagnosed during pregnancy in terms of literature.

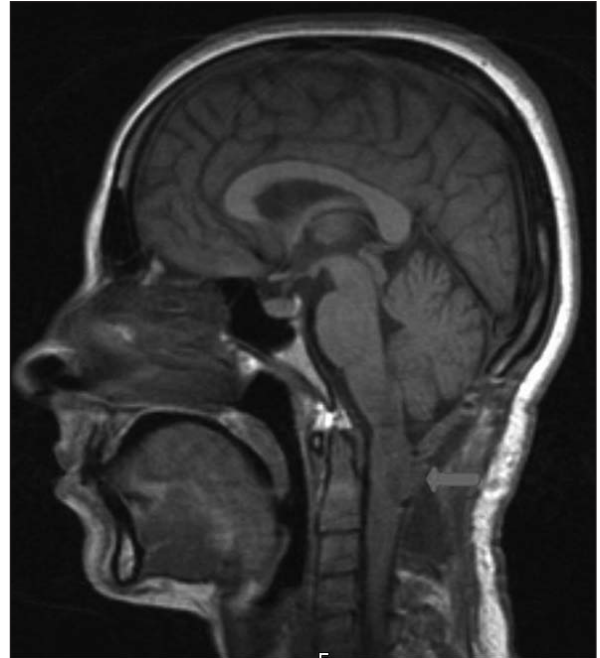
## Case

The 28-year-old patient with Gravida 3, Parity 2 applied to our clinic at her 26th gestational week for complaints of persisting headache, numbness at her left arm and leg and swelling on her neck. There were two cesareans on her obstetric history. First baby was lost due to hydrocephaly when two years old. At her first trimester scanning test who had her follow-up at an external center, free beta-hCG was 39.3 ng/mL (1.00 MoM), PAPP-A was 6.3 mIU/mL (2.75 MoM) and nuchal transparency was 1 mm. According to these values, Down syndrome combination risk at first trimester scan was calculated as 1/8236.

At 26th gestational week, the patient was consulted with neurosurgery department due to her neurological complaints. At her neurological examination, there was hoarseness; motor forces were found as distal 4/5 and proximal 3/5 at her upper extremity and as 3/5 at her lower extremity. Motor forces were distal 2/5 and proximal 1/5 at her left upper extremity and 3/5 at her left lower extremity. Left lower extremity was found as hypoesthetic and left upper extremity as distal anesthetic and proximal hypoesthetic. The mass compressing spinal cord on medulla oblongata C2-C3 level was observed on Magnetic Resonance Imaging (MRI). The patient was established the preliminary diagnosis as medulla oblongata located cranial tumor (Fig. 1). Twenty-four mg/day methylprednisolone was administrated to the patient in order to decrease the distinctive edema around the mass and to reduce clinical symptoms. The patient was hospitalized at the neurosurgery department and followed by weekly perinatological consultation. An operation was decided when mental confusion and shortness of breath developed despite the methylprednisolone administration. As the patient was under a high dose of methylprednisolone treatment, betamethazone treatment was not additionally applied in terms of fetal lung maturation. Before operation, 250 mg hydroxyprogesterone capronate was applied to



**Figure 1.** Preoperative view of anaplastic astrocytomas located at medulla oblongata.



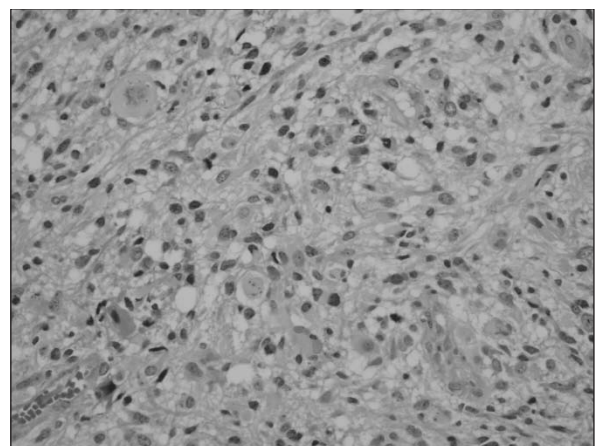
**Figure 2.** Postoperative view of anaplastic astrocytomas located at medulla oblongata.

the patient intramuscularly before the operation for early labor prophylaxis. Cervical intradural extramedullary tumor excision was done at her 27th gestational week. Tumor was removed completely (Fig. 2). Fetal well-being before the operation was checked by ultrasonography and umbilical artery Doppler (Pulsatility Index: 0.79 and Resistance Index: 0.51). Methylprednisolone treatment was maintained for two weeks after the operation. She was followed up for 3 days in intense care unit in the neurosurgery department during postoperative period. Pathology result was reported as anaplastic astrocytoma (WHO grade 3) observed as 4 mitoses at 4 large enlargement areas displaying hypercellularity and distinctive pleomorphism (Figure 3).

The patient was evaluated by neurosurgeons via pathology results and it was decided to apply radiotherapy. The patient was consulted by perinatology department in terms of radiotherapy during pregnancy. It was evaluated again with neurosurgery department to postpone radiotherapy at least until 34th gestational week of patient who was not detected any pathology during obstetric examination. At the end of consultation, it was decided to postpone

radiotherapy to postnatal period. The patient was taken into weekly follow-up at the perinatology department.

At the examination performed on 30th gestational week, biparietal diamtere was measured as 75 mm, head circumference as 271 mm, abdominal circumference as 242 mm, femur length as 56 mm, approximate birth weight as 1362 gr, pulsatility index at umbilical



**Figure 3.** Anaplastic astrocytomas (WHO Grade 3).

artery Doppler as 0.81 and resistance index as 0.52. Amniotic fluid volume was at normal limits and placenta was posterior wall located. The patient was hospitalized for follow-up after 32nd gestational week. Fetal well-being was followed by daily non-stress test (NST) and umbilical artery Doppler. There was a distinctive muscle weakness on left side of the patient.

At the end of 34th gestational week, 2280 gr live singleton boy baby was delivered by cesarean under general anesthesia. 1st minute Apgar score was 6, and 5th minute Apgar score was 8. Bilateral pomero type tube ligation was performed during operation. The baby was followed up in newborn intensive care unit for 19 days after delivery. The baby did not need surfactant and discharged in good condition without any neonatal complication. No postoperative early or late complication was observed in the patient and discharged on her postoperative 3rd day.

Residue lesion with 2-3 mm diameter was detected on medulla oblongata level via MRI performed on postoperative 5th day. There was minimal edema around the lesion. 5 cures of radiotherapy were applied to the patient beginning from postoperative 7th day. Concomitantly, 8 mg/day dexamethasone treatment was initiated. The follow up of the patient is still performed in a multidisciplinary way by radiation oncology, neurosurgery and medical oncology departments. The follow-up of the baby is maintained by our well child polyclinic and no pathological finding has been detected.

## Discussion

The management of intracranial tumors during pregnancy differs clinically. Intracranial tumors the most frequently observed in women at their reproductive periods are glial tumors followed by meningiomas and acoustic neuromas.

Pregnancy does not cause any increase in the risk of brain tumor. However, pregnancy affects the biological behaviors of glial tumors,

meningiomas, vascular tumors and pituitary adenoma. This may cause differentiation in appearance time of first symptoms and development rate of symptoms.<sup>6</sup> Tumors behave different in different periods of pregnancy. Glioms often appear at first trimester while spinal vascular tumors appear at third trimester.<sup>7</sup>

In our case, the patient applied to our clinic at her 26th gestational week due to the complaints of headache and numbness at her left upper and lower extremities. These complaints associated with the intracranial pressure were compatible with the case series in the literature. While it is expected that tumor is generally located at cerebral hemisphere at reproductive period, a mass located at medulla oblongata was observed in our case. No neural deficit was observed at the neurological examination of our case except motor force loss at left upper and lower extremities and hoarseness.

Upon the detection of medulla oblongata located tumor and edema around lesion via MRI, 24 mg/day methylprednisolone was administered. Upon the development of mental confusion and shortness of breath despite the treatment, an operation was decided. Cervical intradural extramedullary tumor excision was performed at her 27th gestational week. Fetal well-being was checked by ultrasonography and umbilical artery Doppler before and after the operation. Fetal heart rate during the operation was followed up by hand Doppler device hourly. When the literature was researched, intraoperative fetal monitorization was performed to the patient who was at 26th gestational week and the delivery was performed by emergency cesarean upon the detection of fetal bradycardia.<sup>8</sup>

In the study performed, congenital anomaly and fetal loss associated with radiotherapy have not been observed at advanced gestational weeks; however, the increase in childhood leukemia incidence.<sup>10</sup> In our case, the family was informed about the possible risks of radiotherapy and it was decided to postpone treat-

ment to the postpartum period. It was decided to perform the delivery by cesarean at 34th gestational week in accordance with the current literature information<sup>9</sup> and the suggestions of related departments (Obstetrics and Gynecology, Pediatrics, Neurosurgery, Medical Oncology, Radiation Oncology, Anesthesia and Reanimation).

In our case, cesarean was performed under general anesthesia. General anesthesia is preferred in such cases within the literature due to increased intracranial pressure and theoretical increased cerebral trunk herniation risk.<sup>11</sup>

Treatment of brain tumors during pregnancy should be personalized. Surgery is an applicable treatment option in patient group which desire to continue pregnancy. Surgical indication should be decided by considering criteria such as intracranial pathology during diagnosis, gestational week and desire of family. If a small tumor without neurological diagnoses is in question, surgery can be postponed to the end of pregnancy. As in our case, surgical treatment should be applied if any worsening occurs in vital functions. Development of neurological deficits during progress of disease increases the possibility of delivery by cesarean, preterm delivery and support of newborn intense care unit. Radiotherapy treatment can be postponed to postpartum period by informing family (as in our case) only in chosen cases.

## Conclusion

New wide-scale case series are needed to help the management of these rare cases. The treatment should be performed in tertiary centers and by a multidisciplinary approach

(Obstetrics and Gynecology, Pediatrics, Neurosurgery, Medical Oncology, Radiation Oncology, Anesthesia and Reanimation) in order to obtain the best obstetric and neurological results.

## References

1. Burger PC, Green SB. Patient age, histologic features and length of survival in patients with glioblastoma multiforme. *Cancer* 1987; 59: 1617-25.
2. Berens ME, Rutka JT, Rosenblum ML. Brain tumor epidemiology, growth and biologic behaviour in the glioblastoma multiforme. A postmortem study of 50 cases. *Cancer* 1983; 52: 2320-33.
3. Stevenson CB, Thompson RC. The clinical management of intracranial neoplasms in pregnancy. *Clin Obstet Gynecol* 2005; 48: 24-37.
4. Roelvink NC, Kamphorst W, van Alphen HA, Rao BR. Pregnancy-related primary brain and spinal tumors. *Arch Neurol* 1987; 44: 209-15.
5. Haas JF, Janisch W, Staneczek W. Newly diagnosed primary intracranial neoplasms in pregnant women: a population-based assessment. *J Neurol Neurosurg Psychiatry* 1986; 49: 874-80.
6. Weinberg HJ. Demyelinating and neoplastic diseases in pregnancy. *Neurol Clin* 1994; 12: 509-26.
7. Roelving NC, Komphorst W, Von Alphen HA, Rao BR. Pregnancy-related primary brain and spinal tumors. *Arch Neurol* 1987; 44: 209-15.
8. Rosen MA. Management of anesthesia for the pregnant surgical patient. *Anesthesiology* 1999; 91: 1159-63.
9. Vougioukas VI, Kyroussis G, Glasker S, Tatagiba M, Scheufler KM. Neurosurgical interventions during pregnancy and the puerperium: clinical considerations and management. *Acta Neurochir* 2004; 146: 1287-92.
10. Pimperl LC. Radiation as a Nervous System Toxin. *Neurol Clin* 2005; 23: 571-97.
11. Smith IF, Skelton V. An unusual intracranial tumour presenting in pregnancy. *Int J Obstet Anesth* 2007; 16: 82-5.
12. Abacıoğlu U, Çetin İ, Akgün Z. Erişkin Glioblastome multiforme tanılı hastalarda radyoterapi sonuçları ve prognostik faktörler. *Türk Onkoloji Dergisi* 2004; 19: 112-8.