

Treatment of Viable Cesarean Scar Ectopic Pregnancy with Intraamniotic Methotrexate Injection

Orhan Ünal, Oluş Api, Bülent Kars, Salim Korucu, Çiğdem Korucu, Sadullah Bulut

Kartal Dr. Lütfi Kırdar Eğitim ve Araştırma Hastanesi, Kadın Doğum Kliniği, İstanbul

Abstract

Objective: TPregnancy in previous cesarean scar is the rarest form of ectopic pregnancy. We aimed to present a case of cesarean scar ectopic pregnancy that was successfully treated with intraamniotic methotrexate injection under ultrasonographic guidance.

Case: A 41-year-old woman, gravida 4, para 2, abortus 1, with a history of two caesarean sections, presented at 5 weeks' gestation and requested pregnancy termination. Upon transvaginal ultrasonography, a hypoechogenic round-shaped mass image, 10x9 mm in diameter - similar to gestational sac - which was localized on Kerr incision, just upon the internal cervical os, was identified. Neither yolk sac nor fetal pole was identified. Serum beta-hCG was 7595 mIU/ml. The patient was re-examined a week later. Transvaginal ultrasonography revealed that the gestational sac diameter proceeded to 24x15 mm with a fetal pole with cardiac activity and beta-hCG was 14000 mIU/ml. Intraamniotic methotrexate (MTX) (10 mg) injection was applied under ultrasonographic guidance. The hemodynamically stable patient was followed on outpatient basis. Serum beta-hCG levels were 20252 mIU/ml and 19399 mIU/ml, with one week intervals. Gestational sac diameter decreased to 15x10 mm with loss of the fetal pole image. Due to the increasing levels of beta-hCG, intramniotic MTX injection was repeated at a dose of 20 mg, 2 weeks after the first injection. Thereafter, the patient was followed with serial ultrasonography and serum beta-hCG monitorization. Cesarean scar pregnancy was completely resorbed upon 9 weeks interval.

Conclusion: Ultrasound-guided methotrexate injection is a successful alternative to terminate cesarean scar pregnancy.

Keywords: Cesarean scar pregnancy, conservative treatment, intraamniotic methotrexate

Canlı sezaryen skar gebeliğinde intraamniotik methotrexat enjeksiyonu ile başarılı tedavi

Amaç: Nadir bir ektopik gebelik türü olan bir sezaryen skar gebelik olgusunun sunulması ile tanı ve tedavi modalitelerinin literatür ışığında tartışılması.

Olgu: Kırkbir yaşında G4P2A1 olan hastanın 9 yıl ve 3 yıl önce 2 kez sezaryen seksiyon ile doğum yaptığı öğrenildi. Bir haftalık adet rötari bulunan hasta aile planlaması isteği ile kliniğimize başvurdu. Yapılan transvajinal ultrasonografide (TVUSG) internal os'un hemen üstünde eksantrik yerleşimli, Kerr insizyon hattının üzerinde gestasyonel kese ile uyumlu hipoekojen halka şeklinde ve 10x9 mm çapında yapı izlendi. İçinde yolk sac ve fetal pol izlenmedi. Hastanın beta-hCG düzeyi 7595 mIU/ml olarak geldi. Bir hafta sonra tekrarlanan TVUSG'de gestasyonel kesenin 24x15 mm çapa ulaştığı ve içinde kalp atımı izlenen fetal imge olduğu gözlemlendi. Beta-hCG düzeyi 14000 mIU/ml olarak geldi. Hastaya sezaryen skar gebelik tanısı ile TVUSG eşliğinde gestasyonel kese içine, intraamniotik 10 mg methotrexate enjeksiyonu yapıldı. Kanaması olmayan hasta ayaktan takibe alındı. Yapılan takiplerde hastanın beta-hCG düzeyi 1 hafta ara ile 20252 mIU/ml ve 19399 mIU/ml geldi, gestasyonel kese 15x10 mm'ye gerileyerek fetal imge görüntüsü kayboldu. Beta-hCG düzeyinin düşmemesi-aksine artması-nedeniyle, birinci methotrexat enjeksiyonunu takiben 2 hafta sonra, yeniden TVUSG eşliğinde ikinci intraamniotik methotrexat enjeksiyonu (20 mg) yapıldı. Beta-hCG takibine alınan hastanın haftalık takiplerinde beta-hCG değerinin düştüğü ve gestasyonel kese görüntüsünün rezorbe olduğu izlendi.

Sonuç: Son yıllarda sezaryen sectio ile yapılan doğumların artması nedeniyle uterin skar gebelikler de daha sık gözlenmeye başlamıştır. Uterin skar gebeliğin tedavisinde TVUSG eşliğinde intraamniotik methotrexat enjeksiyonu etkin ve başarılı bir yöntemdir.

Anahtar Sözcükler: Sezaryen skar gebelik, konservatif tedavi, intraamniotik methotrexat.

Background

The pregnancy implanted in cesarean scar is the rarest form of the ectopic pregnancy, is a clinic case containing life-threatening situation. Since it is so rare, there isn't any agreed clinical administration. The data in the literature is mostly formed of the case studies. In English literature, as from 2002, 66 cesarean scar pregnancy cases were reported.¹ This figure reflects increasing cesarean births and the use of transvaginal ultrasonography for diagnosing scar pregnancies. Former cesarean cases, the risk factors for scar pregnancy are dilatation, and curettage history, placental pathology, ectopic pregnancy history and in vitro fertilization cycle.^{1,2} Among the treatment options, there are direct methotrexate or potassium chloride injection and/or systemic methotrexate injection, vaginal sonography, as well as embryo aspiration, spooling treatment, removing the gestational tissue through laparotomy, dilatation and curettage, transarterial uterine artery embolization.²⁻⁶ However, in the extent of the examined case series, direct methotrexate injection, accompanied

by ultrasonic monitoring is the most appropriate option.³

We aimed to discuss the diagnosis, treatment, follow up approaches in light of the literature, to emphasize the importance of transvaginal sonography in early diagnosis and follow-up.

Case

A 41-year-old woman, with a history of two caesarean sections, which one was 9 years ago and the other 3 years ago. The patient who has 1 week menstrual latency, requested the hospitalization for abortion. Upon transvaginal ultrasonography, a hypoechogenic round-shaped mass image, 10x9 mm in diameter -similar to gestational sac- which was localized on Kerr incision, just upon the internal cervical ostium, was identified. Neither yolk sac nor fetal pole was identified. Serum beta-hCG was 7595 mIU/ml. The patient was re-examined a week later. Transvaginal ultrasonography revealed that the gestational sac diameter proceeded to 24x15 mm with a fetal pole with cardiac activity and beta-hCG was 14000 mIU/ml. The patient has

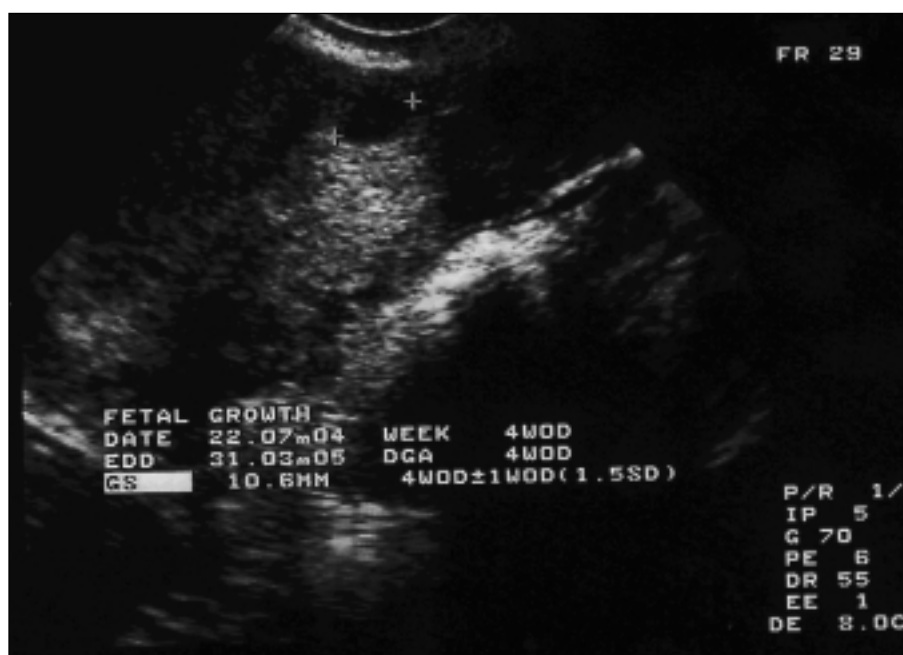

Figure 1. Ultrasonographic image of scar pregnancy.

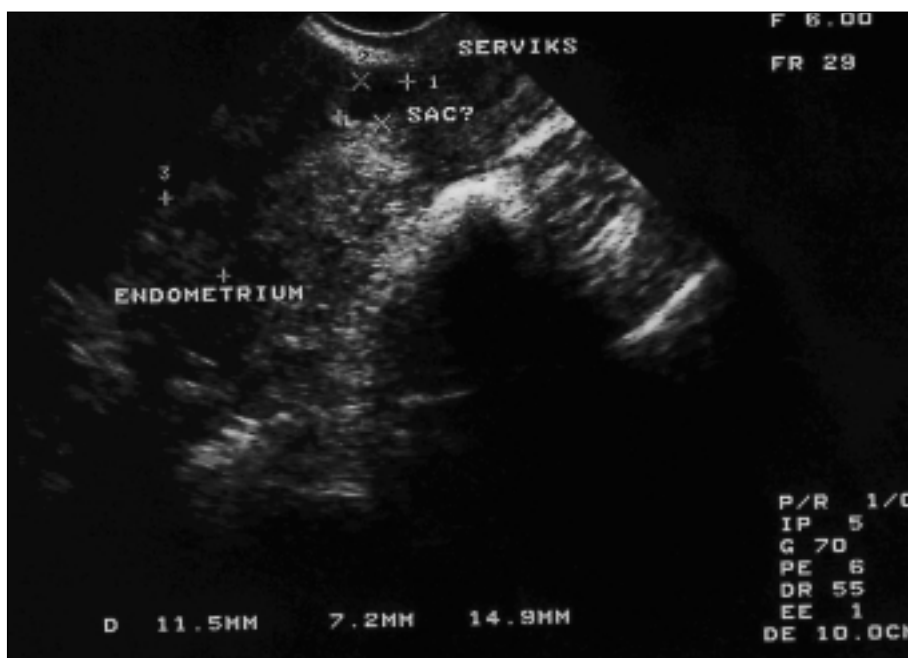


Figure 2. Ultrasonographic image of scar pregnancy.

undergone 10 mg methotrexate injection accompanied by TVUSG directly into the uterus upon the cesarean scar pregnancy diagnosis. The patient who hasn't hemorrhage underwent an outpatient follow up. In the monitoring, beta-hCG level was measured 20252 mIU/ml and 19399 mIU/ml, gestational mass was reduced to 15 x 10 mm and fetal image was disappeared. Since Beta-hCG level augments, after first methotrexate injection, within 2 weeks, second intraamniotic methotrexate injection was made (20 mg). After 3 days of second dose methotrexate injection, the patient flood during 10 days. 10th day of the vaginal bleeding, transvaginal ultrasonography was repeated and showed that the diameter of the gestational sac was reduced to 5 x 5 mm and serum beta-hCG level was reduced to 1778 mIU/ml. Serum beta-hCG was 3259 mIU/ml after one week. The vaginal hemorrhage stopped and transvaginal USG showed that the gestational sac was still 5 x 5 mm. Weekly beta-hCG follow up indicated the values and the image of gestational sac disappeared. Figure 1 and 2 show the weekly gestational sac

and serum beta-hCG results. Consequently, cesarean scar pregnancy was completely resorbed in the end of 9th week

Discussion

Cesarean scar pregnancy was a contraindication of the cesarean cases that are showing a significant increase in recent years. In a series of 12 cases studied by Seow et al reported that, cesarean scar pregnancy frequency was estimated 1/2226 and scar pregnancy rate was 6.1% for women that have at least one cesarean birth and one ectopic pregnancy.³ The pregnancy age was 5-12 weeks on diagnosis, and the time between latest cesarean and scar pregnancy was found 6-12 months. To 12 patients, direct methotrexate or potassium chloride injection and/or systemic methotrexate injection, vaginal sonography, as well as embryo aspiration, spooling treatment, removing the gestational tissue through laparotomy, dilatation and curettage methods were applied and 11 of 12 patients retained their reproductive ability. And one patient who had undergone dilatation and curettage had hysterectomy

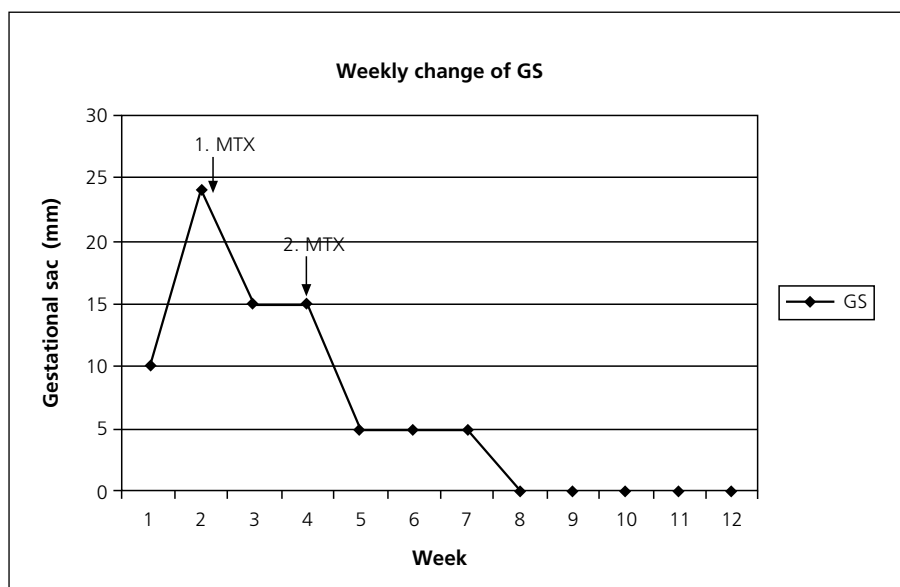


Figure 1. Weekly change in diameter of gestational sac (GS).

because of excessive bleeding. However, in the extent of the examined case series, direct methotrexate injection, accompanied by ultrasonic monitoring is the most appropriate option and surgical/invasive methods should be avoided because of the high morbidity. Our case is a with a history of two caesarean sections, which one was 9 years ago and the other 3 years ago. The pregnancy age is weeks on the diagnosis. In order to be sure of

scar pregnancy, ultrasonography of the patient was repeated 1 week later and showed that the diameter of gestational sac increased and fetal image appeared, beta-hCG was elevated. 10 mg MTX injected to the patient accompanied by transvaginal USG. During the 15 days follow up, despite the fetal image disappeared beta-hCG didn't reduce, in contrary elevated and through second USG 20 mg MTX injection was applied. Following the second

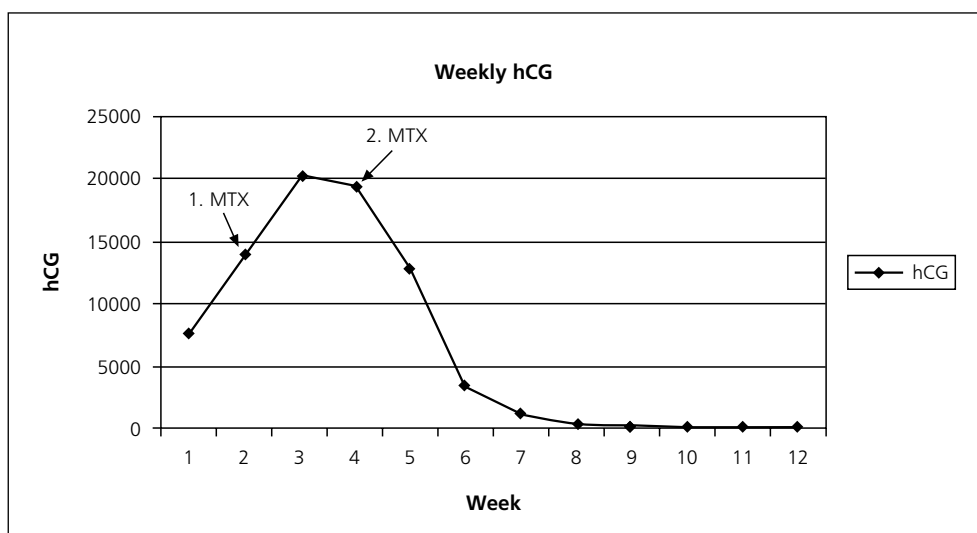


Figure 2. Weekly serum beta-hCG.

treatment, the scar pregnancy begun to resorb rapidly. Since the scar pregnancy is a rare form of the ectopic pregnancy, treatment schedule is different according to the patient. The data in the literature is mostly formed of the case reports. Based on the presented case, transvaginal USG and serum beta-hCG are important indicators in the follow up of the scar pregnancy treatment. Beta-hCG values that don't reduce or indifference of ultrasonographic pregnancy image are related to the unsuccessful treatment or readministration of dose. On the other hand, resorption of the scar pregnancy ultrasonographic image, administered intraamniotic MTX may last 2-12 months.^{3,7} Researching the literature, 54% of the ectopic pregnancy cases delivered 2 or more cesarean fetus and 30% had dilatation or curettage operation. For the women with ectopic pregnancy, placental pathology (placenta previa) history and the ones with 2 or more cesarean (in particular, because of bottom-down presentation), the scar pregnancy development is more probable.¹

In conclusion, cesarean scar pregnancies are frequently observed in recent years as cesarean births are increased. Being aware of this possibility and using early transvaginal USG augment the early diagnosis and the success of the conservative

treatment and prevents the surgical operation requirements that may cause hysterectomy.

References

1. Maymon R, Halperin R, Mendlovic S, Schneider D, Herman A. Ectopic pregnancies in a Cesarean scar: review of the medical approach to an iatrogenic complication. *Hum Reprod Update*. 2004 Nov-Dec;10(6):515-23. *Epub* 2004 Sep 16.
2. Maymon R, Halperin R, Mendlovic S, Schneider D, Vaknin Z, Herman A, Pansky M. Ectopic pregnancies in Cesarean section scars: the 8 year experience of one medical centre. *Hum Reprod* 2004; 19(2): 278-84.
3. Seow KM, Huang LW, Lin YH, Lin MY, Tsai YL, Hwang JL. Cesarean scar pregnancy: issues in management. *Ultrasound Obstet Gynecol* 2004; 23(3):247-53.
4. Doubilet PM, Benson CB, Frates MC, Ginsburg E. Sonographically guided minimally invasive treatment of unusual ectopic pregnancies. *J Ultrasound Med* 2004; 23(3): 359-70.
5. Yang MJ, Jeng MH. Combination of transarterial embolization of uterine arteries and conservative surgical treatment for pregnancy in a cesarean section scar. A report of 3 cases. *J Reprod Med* 2003; 48(3): 213-6.
6. Arslan M, Pata O, Dilek TU, Aktas A, Aban M, Dilek S. Treatment of viable cesarean scar ectopic pregnancy with suction curettage. *Int J Gynaecol Obstet* 2005; 89(2): 163-6.
7. Haimov-Kochman R, Sciaky-Tamir Y, Yanai N, Yagel S. Conservative management of two ectopic pregnancies implanted in previous uterine scars. *Ultrasound Obstet Gynecol* 2002; 19(6): 616-9.