

Fetal supraventricular tachycardia

Ahmet Karataş¹, Zehra Karataş², Tülay Özlü¹, Beyhan Küçükbayrak³,
Seda Eymen Kılıç¹, Melahat Emine Dönmez¹

¹Department of Obstetrics & Gynecology, Faculty of Medicine, Abant İzzet Baysal University, Bolu, Turkey

²Pediatric Cardiology Division, Department of Pediatrics, Faculty of Medicine, Abant İzzet Baysal University, Bolu, Turkey

³Clinic of Pediatrics, İzzet Baysal State Hospital, Bolu, Turkey

Abstract

Objective: The diagnosis of fetal supraventricular tachycardia (SVT) which can be intermittent or continuous is established by 1:1 atrioventricular conduction in echocardiography, and heart rate between 220 and 240 bpm. We aimed to present a fetal SVT case characterized by the loss of variability and intermittent tachycardia attacks in non-stress test (NST).

Case: The fetus at 32 weeks of gestation was diagnosed with SVT due to the loss of variability at NST, intermittent tachycardia attacks, 230 bpm at echocardiography and regular 1:1 AV conduction. Oral sotalol therapy was initiated to the mother. At the follow-up, spontaneous vaginal delivery was carried out at week 34/7. Upon observing SVT attack for five minutes at eight hour of the birth, oral digoxin therapy was initiated. No additional SVT attack was observed during 3 months of follow-up.

Conclusion: Intermittent fetal SVTs may progress only by the loss of variability at NST during non-attack periods. We believe that it would be useful to follow-up cases closely who have normal biophysical profile except the loss of variability at NST in terms of fetal tachyarrhythmia.

Key words: Fetal supraventricular tachycardia, non-stress test, sotalol.

Fetal supraventriküler taşikardi

Amaç: Aralıklı ya da devamlı olabilen fetal supraventriküler taşikardi (SVT) tanısı, ekokardiografide 1:1 atrioventriküler ileti olması ve kalp hızının 220-240 atım/dakika olması ile konulur. Burada, non-stres testte (NST) variabilite kaybı ve aralıklı taşikardi atakları ile prezente olan bir fetal SVT olgusunu sunmayı amaçladık.

Olgu: Otuz ikinci gebelik haftasında NST'de variabilite kaybı, aralıklı taşikardi atakları, ekokardiografide 230 atım/dk kalp hızı ve düzenli 1:1 AV ileti görülen fetüse SVT tanısı konuldu. Anneye oral sotalol tedavisi başlandı. Takipte 34/7 haftada spontan vajinal doğum gerçekleşti. Doğumunun sekizinci saatinde beş dakikalık SVT atağı saptanması üzerine oral digoksin tedavisi başlandı. Olgunun üç aylık takip süresinde tekrar SVT atağı gözlenmedi.

Sonuç: Aralıklı fetal SVT'ler ataksız dönemlerde sadece NST'de variabilite kaybı ile seyredebilir. NST'de variabilite kaybı dışında biyofizik profili normal olan olguların fetal taşıyımını yönünden yakın takip edilmesinin faydalı olacağı kanısındayız.

Anahtar sözcükler: Fetal supraventriküler taşikardi, non-stres test, sotalol.

Introduction

Fetal dysrhythmias are categorized under three groups which are tachyarrhythmia, bradyarrhythmia and irregular cardiac rhythm. If fetal heart rate is above 180 rpm, it is tachyarrhythmia; if it is below 100 rpm, then it is bradyarrhythmia.^[1] Fetal tachyarrhythmia incidence in pregnant is reported between 0.4 and 0.6%.^[2]

The reason of 70-80% of fetal tachyarrhythmias which are one of the major causes of fetal distresses is the supraventricular tachycardia.^[3] Serious cardiac defects such as ventricular septal defect, aortic stenosis, coarctation of aorta, cardiac tumor, left atrial isomerism and Ebstein anomaly may be seen in cases with fetal tachyarrhythmia.^[4]

Correspondence: Dr. Ahmet Karataş, Abant İzzet Baysal Üniversitesi Tıp Fakültesi Kadın Hastalıkları ve Doğum Anabilim Dalı, Bolu.
e-mail: akaratas1973@hotmail.com

Received: Ekim 9, 2013; **Accepted:** Kasım 8, 2013

Available online at:
www.perinataljournal.com/20140221010
doi:10.2399/prn.14.0221010
QR (Quick Response) Code:



Fetal SVT diagnosis is established by the detection of regular 1:1 atrioventricular (AV) conduction by M-mod or pulsed-wave Doppler in fetal echocardiography.^[2] Fetal heart rate is generally 220-240 bpm. The most etiological reason is reported as the AV re-entry occurring through accessory pathway. Fetal SVT may be intermittent or continuous, and may cause non-immune hydrops fetalis.^[2,5] Hydrops fetalis is one of the most significant factors for estimating perinatal outcomes.^[6] There is the risk of congestive heart failure and mortality risk at the rate of 27%.^[6]

The anti-arrhythmic drugs that are used most in fetal SVT treatment are digoxin, sotalol, flecainide and amiodarone. In this article, fetal SVT case treated by sotalol was presented since it is rare, and displayed the loss of variability at non-stress test (NST).

Case Report

In 34-year-old (Gravida 3, Parity 2, Live 2), the loss of variability at NST and fetal tachycardia which took 6 minutes were observed at 32 weeks of gestation (**Fig. 1**). The case which did not show any cardiac defect in fetal echocardiography and had 140 bpm of heart rate was referred to our clinic when fetal heart rate was found to

be above 210 bpm at NST in the control two weeks later. According to the examination, weeks of gestation were 34 according to last menstrual period and fetal biometry was consistent with 36 weeks. The score of biophysics was 8 and there was no fetal hydrops finding. Fetal heart rate was 230 bpm in fetal echocardiography (**Fig. 2**). Fetal SVT diagnosis was established when regular 1:1 AV conduction was observed.

Upon the observation of tachycardia attack which took 10 minutes in the follow-up by continuous fetal monitorization, oral sotalol therapy (160 mg/day, 2 doses) was initiated to mother who had no arrhythmia history and found to have normal QTc interval in electrocardiographic (ECG) examination. After the treatment, fetal tachycardia which took 25-30 minutes was observed two times in the first 24 hours. At the 35th hour of treatment, early membrane rupture developed and 2800 g female baby (first minute Apgar score: 7; 5th minute Apgar score: 9) was delivered vaginally at 42nd hour after spontaneous labor at 342/7 week.

Upon SVT attack which took 5 minutes at postnatal 8th hour, oral digoxin was administered (1x1 drop) to the newborn who had normal findings for physical examination, full blood count, biochemical tests, thyroid func-

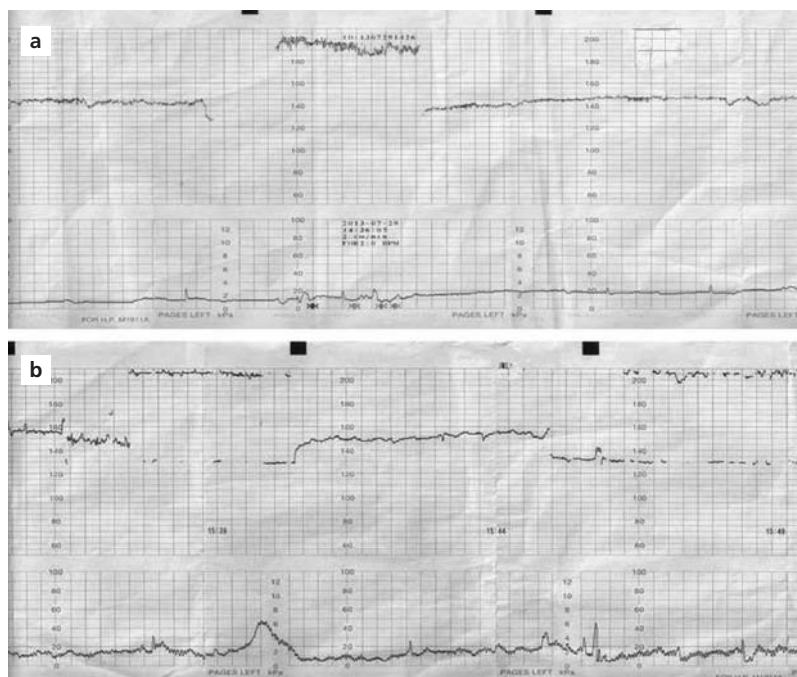


Fig. 1. (a, b) Fetal tachycardia and variability loss in non-stress test.

tion tests, ECG and systolic functions, and found to have patent foramen ovale in the echocardiographic assessment. The case which did not relapse arrhythmia in the follow-up was discharged from the hospital and no SVT attack was observed during 3-month follow-up period.

Discussion

Fetal tachyarrhythmia is one of the reasons of fetal distress. Fetal SVT which is one of the most common reasons of fetal tachyarrhythmias is the cardiac arrhythmia in which fetal heart rate is 220-300 bpm and AV conduction is 1:1. Although fetal SVT is observed generally at 2nd and 3rd trimester, it may also be seen in first trimester.^[7] Fetal SVT may be intermittent or continuous. In case that it takes longer than 12 hours, it may cause heart failure, non-immune hydrops fetalis, preterm labor or fetal losses. In our case, biophysical profile was normal despite the loss of variability at NST.

The approach in fetal SVT is determined according to the gestational age, duration and frequency of attack, and the presence of heart failure and hydrops. The incidence rate of non-immune hydrops is higher at early weeks.^[4] It is reported that follow-up can be carried out in cases with short-term attack (<1-2 min.) and no heart failure developed; however, it is suggested to do anti-

arrhythmic treatment which is continuous and no heart failure is developed.^[8]

Anti-arrhythmic treatment can be applied to the fetus through either direct cordocentesis or mother transplacentally. Since repeating initiatives may be needed and there is 1% risk of perinatal mortality by cordocentesis, transplacental method is preferred widely. However, in the presence of hydrops, the effect of transplacental drug is decreased. In a study where transplacental digoxin, sotalol and flecainide were compared on 159 fetal tachyarrhythmia cases, it was reported that digoxin and flecainide were more effective than sotalol on both fetal SVT and atrial flutter. It was seen that fetal SVT returned to normal rhythm after median 3 days by digoxin, median 4 days by flecainide, and median 12 days by sotalol.^[4] Although digoxin (1.5-2 mg in the first 2 days, then 0.375-1 mg/day) or sotalol (160-400 mg/day, 2-3 doses) was reported to be effective as the first preference in non-hydropsic cases, there has been no controlled prospective study yet showing superiority of anti-arrhythmic drugs over each other.^[9] Generally, if no response to treatment is observed within three days, either dosage is increased or it is initiated to administer a second anti-arrhythmic drug.^[10]

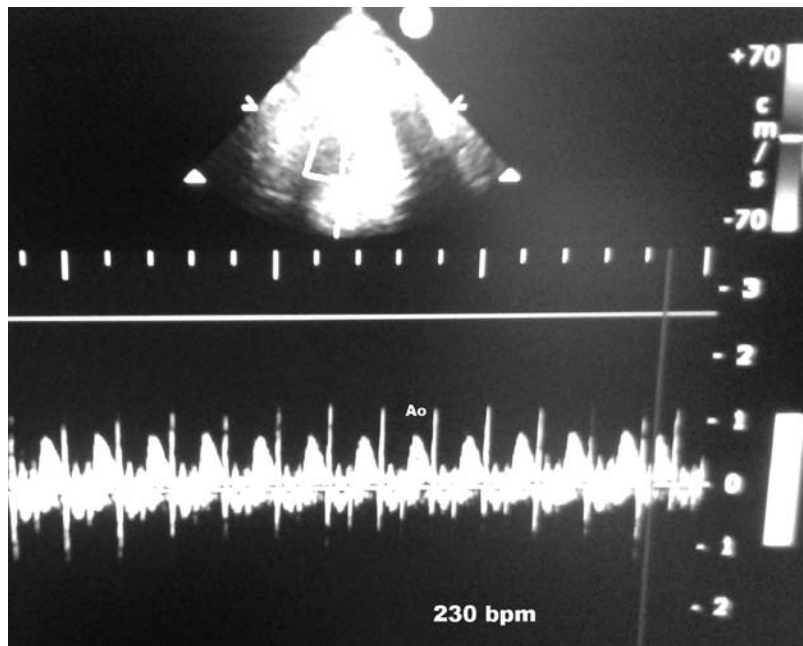


Fig. 2. Fetal heart rate in the Doppler examination obtained from aortic flow is 230 bpm.

One of the reasons of fetal SVT is the Wolf-Parkinson-White (WPW) syndrome (21%) among pre-excitation syndromes.^[11] However, there is still no fetal cardiac electrophysiological assessment method to use in prenatal diagnosis of WPW syndrome. Yet, it is reported that fetal WPW diagnosis may be established by fetal magnetocardiography which is a non-invasive method.^[12] Establishing the diagnosis of WPW syndrome is very important for choosing STV treatment since using digoxin in WPW syndrome which may cause AV conduction abnormalities is contraindicated.^[13]

Sotalol is a non-selective beta-blocker type of anti-arrhythmic drug which has better placental transmission than digoxin.^[14] It is reported that sotalol can be used safely in also hydropic cases as a first preference.^[10] However, it may cause exhaustion, inappetence, headache, palpitation, chest pain, emesis, bradycardia, proarrhythmic effect in the mother and sudden fetal deaths.^[15] Mother should be questioned in terms of arrhythmia history before sotalol administration due to proarrhythmic effect, treatment should be initiated after QTc interval is assessed in ECG. Due to the possibility of close monitorization of maternal heart rate, it is recommended to carry out treatment by hospitalization.^[15] In our non-hydropic case, anti-arrhythmic drug was administered due to frequent repeat and long duration of fetal SVT. Sotalol was preferred as anti-arrhythmic drug since it has been reported that sotalol has been effective in fetal SVT treatment recently and that fetal WPW syndrome could not be ruled out. During the treatment, no prolongation was detected in the maternal QTc duration. However, two fetal SVT attacks were observed during the follow-up and preterm labor was carried out at week 34/7. The case, which could not be found to have WPW syndrome at postnatal examination and observed to have SVT attack again, was successfully treated by digoxin.

Conclusion

Diagnoses and treatments of fetal tachyarrhythmias are very important due to the fact that they may cause fetal distress. We presented this case to highlight the significance of close follow-up of cases in terms of fetal tachyarrhythmias which have normal biophysical profile except the loss of variability at non-stress test, to contribute to the fetal SVT follow-up, and to share our experience.

Conflicts of Interest: No conflicts declared.

References

1. Copel JA, Liang R, Demasio K, Ozeren S, Kleinman CS. The clinical significance of the irregular fetal heart rhythm. *Am J Obstet Gynecol* 2000;182:813-9.
2. Oudijk MA, Visser GH, Meijboom EJ. Fetal tachyarrhythmia - Part 1: diagnosis. *Indian Pacing Electrophysiol J* 2004;4:104-13.
3. van Engelen AD, Weijtens O, Brenner JI, Kleinman CS, Copel JA, Stoutenbeek P, et al. Management outcome and follow-up of fetal tachycardia. *J Am Coll Cardiol* 1994;24:1371-5.
4. Jaeggi ET, Carvalho JS, De Groot E, Api O, Clur SA, Rammeloo L, et al. Comparison of transplacental treatment of fetal supraventricular tachyarrhythmias with digoxin, flecainide, and sotalol: results of a nonrandomized multicenter study. *Circulation* 2011;124:1747-54.
5. Strasburger JF, Wakai RT. Fetal cardiac arrhythmia detection and in utero therapy. *Nat Rev Cardiol* 2010;7:277-90.
6. Simpson JM, Sharland GK. Fetal tachycardias: management and outcome of 127 consecutive cases. *Heart* 1998;79:576-81.
7. Porat S, Anteby EY, Hamani Y, Yagel S. Fetal supraventricular tachycardia diagnosed and treated at 13 weeks of gestation: a case report. *Ultrasound Obstet Gynecol* 2003;21:302-5.
8. Cuneo BF, Strasburger JF. Management strategy for fetal tachycardia. *Obstet Gynecol* 2000;96:575-81.
9. Api O, Carvalho JS. Fetal dysrhythmias. *Best Pract Res Clin Obstet Gyn* 2008;22:31-48.
10. van der Heijden LB, Oudijk MA, Manten GT, Ter Heide H, Pistorius L, Freund MW. Sotalol as first-line treatment for fetal tachycardia and neonatal follow-up. *Ultrasound Obstet Gynecol* 2013;42:285-93.
11. Hahurij ND, Blom NA, Lopriore E, Aziz MI, Nagel HT, Rozendaal L, et al. Perinatal management and long-term cardiac outcome in fetal arrhythmia. *Early Hum Dev* 2011;87:83-7.
12. Kähler C, Schleussner E, Schneider U, Seewald HJ. Prenatal diagnosis of the Wolf-Parkinson-White-syndrome by fetal magnetocardiography. *BJOG* 2001;108:335-6.
13. Wellens HJ, Durrer D. Effect of digitalis on atrioventricular conduction and circus movement tachycardia in patients with the Wolf-Parkinson-White syndrome. *Circulation* 1973;47:1229-33.
14. Oudijk MA, Ruskamp JM, Ambachtsheer EB, Ververs FF, Stoutenbeek P, Visser GH, et al. Treatment of fetal tachycardia with sotalol: transplacental pharmacokinetics and pharmacodynamics. *J Am Coll Cardiol* 2003;42:765-70.
15. Krapp M, Kohl T, Simpson JM, Sharland GK, Katalinic A, Gembruch U. Review of diagnosis, treatment and outcome of fetal atrial flutter compared with supraventricular tachycardia. *Heart* 2003;89:913-7.