



First trimester diagnosis of pentalogy of Cantrell: a rare case associated with neural tube defect

Bülent Çakmak, Zeki Özsoy, Mehmet Can Nacar, Fazlı Demirtürk

Department of Obstetrics and Gynecology, Faculty of Medicine, Gaziosmanpaşa University, Tokat, Turkey

Abstract

Objective: The aim of this paper is to discuss a case of pentalogy of Cantrell with neural tube defect diagnosed at the 12th week of pregnancy.

Case: Ectopia cordis, omphalocele with large thoracoabdominal defect and acrania were detected in a fetus during the first trimester ultrasound scan of a 28-year-old, G2, P1 pregnant. The family was informed about the prognosis of pregnancy. After obtaining written informed consent due to the family's decision of termination, the pregnancy was terminated. As a result of post-mortem pathological examination, the prenatal diagnosis has been confirmed.

Conclusion: Pentalogy of Cantrell should be considered in the presence of anterior abdominal wall defect and ectopia cordis in the first trimester prenatal ultrasound screening. Neural tube defects are extremely rare in these cases.

Key words: Pentalogy of Cantrell, ectopia cordis, omphalocele, neural tube defects.

İlk trimesterde tanısı konulan Cantrell pentalojisi: Nöral tüp defektinin eşlik ettiği nadir bir olgu

Amaç: Bu çalışmanın amacı gebeliğin 12. haftasında tanısı konulan nöral tüp defektinin eşlik ettiği Cantrell pentalojisi olgusunu literatür eşliğinde tartışmaktır.

Olgu: Yirmi sekiz yaşında, bir yaşayanı olan gebenin ilk trimester ultrasonografi taraması esnasında fetusta ektopia kordis, omfaloseleli içeren geniş torakoabdominal defekt ve akrani izlendi. Aileye gebelik prognozu hakkında bilgi verildi. Ailenin terminasyon yönünde karar vermesi nedeniyle yazılı onam alındıktan sonra gebelik termine edildi. Postmortem patolojik inceleme sonucu prenatal tanı doğrulandı.

Sonuç: İlk trimester prenatal ultrasonografi taramasında batın ön duvarı defekti ile birlikte ektopia kordis varlığında Cantrell pentalojisi akla gelmelidir. Nöral tüp defektleri bu olgularda oldukça nadir görülmektedir.

Anahtar sözcükler: Cantrell pentalojisi, ektopia kordis, omfalosele, nöral tüp defekti.

Introduction

The pentalogy of Cantrell is a syndrome including abdominal wall, sternum, diaphragm, pericardium, and cardiac defects, which was first defined by Cantrell et al. in 1958.^[1] This syndrome consists of five defects including the defect of midline supra-umbilical anterior abdominal side, the defect of inferior tip of sternum, non-existence of diaphragm side of pericardium, lack of anterior diaphragm and various cardiac anomalies.^[2] Cantrell syndrome is quite rare and its incidence has been reported as 1/100,000.^[3]

Complete pentalogy is quite rare and it is seen more frequently in incomplete cases where one or more components constituting current syndrome exist. It is more frequent among men in the rate of 2:1.^[3] Neural tube defects such as encephalocele, meningomyelocele, anencephaly, spina bifida and craniorachischisis may be seen together with the pentalogy of Cantrell.^[4,5] In this study, we aimed to present the case diagnosed ultrasonographically as the pentalogy of Cantrell accompanied by the acrania at 12 weeks of pregnancy.

Correspondence: Bülent Çakmak, MD.
Yeşilirmak Mah. Bosna Cad. 6. Sok. No: 4/9, Tokat, Turkey.
e-mail: drbulentcakmak@hotmail.com

Received: January 9, 2013; **Accepted:** January 30, 2013

Available online at:
www.perinataljournal.com/20130211017
doi:10.2399/prn.13.0211017
QR (Quick Response) Code:



Case Report

A 28-year-old pregnant with a healthy fetus admitted to the clinic for routine first trimester screening test when she was pregnant for 12 weeks and 3 days. It was learnt from her obstetric history why her first 32-week pregnancy terminated for intrauterine exitus reasons. In the obstetric ultrasonographic evaluation, intrauterine, single, live and with 60 mm crown-rump length, and 12-week-old fetus was observed. Acrania, sternal defect, and ectopia cordis were observed in the ultrasonographic examination (**Fig. 1**). Besides, anterior abdominal wall defect and bowel loops protruded from this defect were seen. By the current findings, the case was diagnosed as the pentalogy of Cantrell. In the cardiac evaluation, the view of four chambers was not seen clearly. In the limb evaluation, pes equinovarus was found in both lower limbs. The family was informed about existing findings and gestational prognosis.

When the family decided to terminate the pregnancy, the written consent was obtained and abortion was done 12 hours later by applying 400 microgram vaginal misoprostol. The patient who had no problem after the abortion was discharged the next day. In the macroscopic examination of the fetus after abortion, defects on thoracic and abdominal wall, acrania and neural tube defect were observed. Bowel loops were observed out of the abdomen and the heart was

observed out of the thorax (ectopia cordis) (**Figs. 2 and 3**). After the pathological examination, thoracic defect and ectopia cordis, anterior abdominal wall defect and the herniation of bowel loops, acrania, and neural tube defects were reported.

Discussion

The pentalogy of Cantrell is a rare syndrome, and its significant characteristic for diagnosis is the existence of omphalocele due to anterior abdominal wall defect, ectopia cordis due to sternal defect and cardiac anomaly together. Diagnosis can be established in the first trimester in the presence of complete and major defects, especially of ectopia cordis and major omphalocele; however, when defects are minor and in incomplete cases, diagnosis may be established in the second trimester.^[6] In our case, the association of major anterior abdominal wall defect and ectopia cordis helped to establish the diagnosis in the first trimester. All components of pentalogy may not exist in all cases. Toyoma et al.^[3] made classification in three groups according to the presence of components constituting the pentalogy. According to that classification, all components exist in Type I; only four defects exist in Type II, and various combinations of the defects exist in Type III as incomplete form. In this case, all components were present and the case was evaluated as Type I.

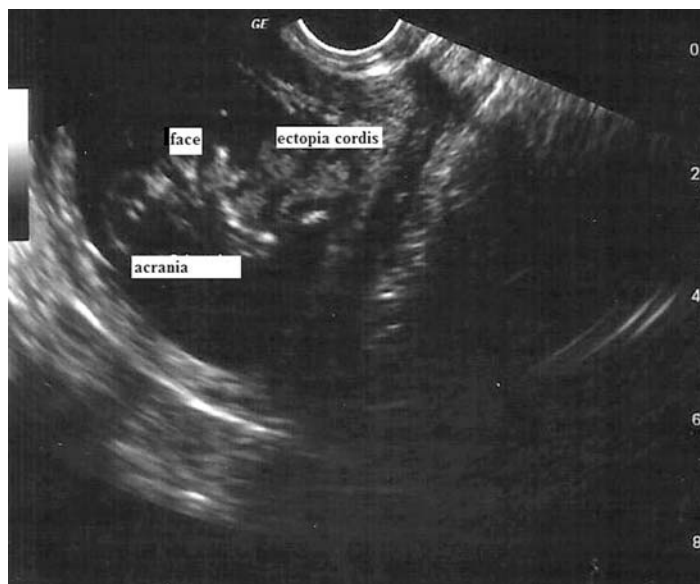


Fig. 1. Ultrasonographic view of the fetus

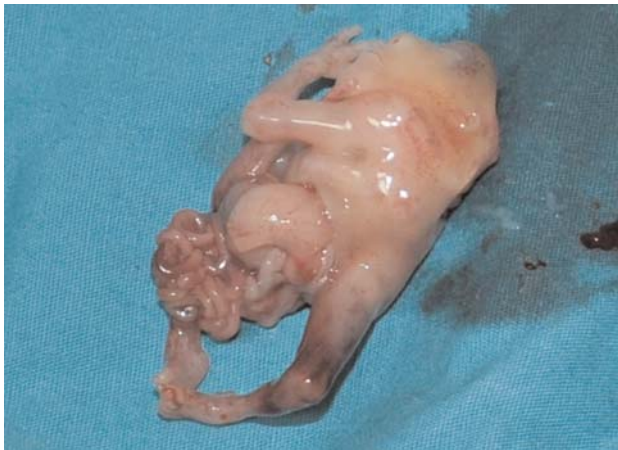

Fig. 2. The view of fetus where the heart is observed out of the thorax and the bowel was observed out of the abdominal cavity.

The etiology of the syndrome is not known completely, it is considered that it appears due to the incapability of mesoderm during the migration on mid-even ventromedial direction at early embryonic phase.^[7] Apart from that, it is stated that it may occur due to mechanical teratogenicity effect associated with chorionic or yolk sac rupture.^[8] In the etiological studies, it has been reported that thoracoabdominal syndrome gene is associated with Xq22-Xq27 or Xq25-Xq26 region according to DNA analyses.^[9,10] However, X-inherited heredity due to mutations in localized genes in X chromosome may be in question in some familial cases.^[11] Yet, no specific genetic disorder has been revealed completely to explain the etiology by this time. Most of the cases are sporadic cases where there is no familial predisposition as in our case.

The prognosis in the pentalogy of Cantrell depends on the level of cardiac anomaly, and the presence and intensity of other accompanying anomalies; however, the syndrome is mostly considered as lethal. The syndrome may sometimes be accompanied by other anomalies related with other systems. While vertebral anomalies are reported in some cases,^[12] vertebral anomalies with pes equinovarus are reported in some cases.^[6] Alanbay et al. reported cleft palate and lip, upper limb hypoplasia, pes equinovarus and vertebral anomaly together with the pentalogy in a 16-week-old pregnancy.^[13] Other anomalies reported with the pentalogy are the anomalies associated with neural tube defect.^[14] Polat et al. reported the presence of cranio-rachischisis in two out of three prenatally diagnosed

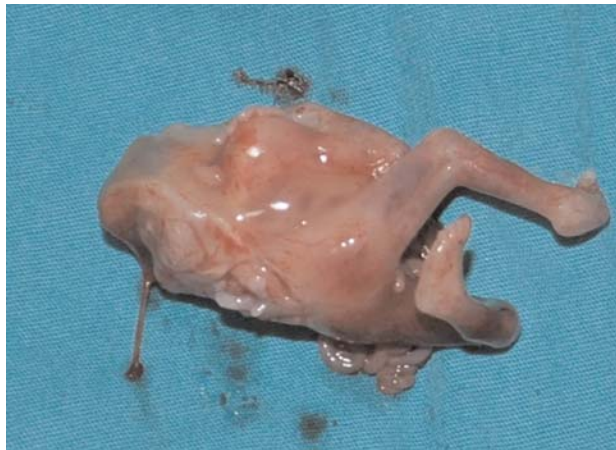

Fig. 3. The view of fetus where acrania and neural tube defect are observed.

pentalogy cases.^[15] In another case presentation, encephalocele was found in the pentalogy of Cantrell prenatally diagnosed at the first trimester.^[16] In our case, acrania, neural tube defect and pes equinovarus were found together with the pentalogy. In this case, the family was informed in detail since the presence of acrania would have a negative effect on fetal prognosis, so the family decided to terminate the pregnancy.

Conclusion

Consequently, the pentalogy of Cantrell should be kept in mind in cases that were found to have cardiac anomaly and/or ectopia cordis together with anterior abdominal wall defect. It should not be forgotten that other system anomalies may exist in cases with the pentalogy of Cantrell, and detailed ultrasonographic examination should be performed accordingly.

Conflicts of Interest: No conflicts declared.

References

1. Cantrell JR, Haller JA, Ravitch MM. A syndrome of congenital defects involving the abdominal wall, sternum, diaphragm, pericardium and heart. *Surg Gynecol Obstet* 1958;107:602-14.
2. Desselle C, Herve P, Toutain A, Lardy H, Sembely C, Perrotin F. Pentalogy of Cantrell: sonographic assessment. *J Clin Ultrasound* 2007;35:216-20.
3. Toyama WM. Combined congenital defects of the anterior abdominal wall, sternum, diaphragm, pericardium and heart: a case report and review of the syndrome. *Pediatrics* 1972;50:778-92.

4. Dane C, Dane B, Yayla M, Cetin A. Prenatal diagnosis of a case of pentalogy of Cantrell with spina bifida. *J Postgrad Med* 2007;53:146-8.
5. Ranganath P, Pradhan M. Complete pentalogy of Cantrell with craniorachischisis: a case report. *J Prenat Med* 2012;6:10-2.
6. Gün I, Kurdođlu M, Müngen E, Muhcu M, Babacan A, Atay V. Prenatal diagnosis of vertebral deformities associated with pentalogy of Cantrell: the role of three dimensional sonography? *J Clin Ultrasound* 2010;38:446-9.
7. Uludađ S, Barbaros ZM, Aksoy F, Erdođan E, Madazlı R. Cantrell sendromu. *Perinatoloji Dergisi* 1999;7:324-7.
8. Groner JI. Ectopia cordis and sternal defects. In: Ziegler MM, Azizkhan RG, Weber TR, editors. *Operative Pediatric Surgery*. New York: McGraw-Hill Inc.; 2003. p. 279-93.
9. Carmi R, Barbash A, Mares AJ. The thoracoabdominal syndrome (TAS): a new X-linked dominant disorder. *Am J Med Genet* 1990;36:109-14.
10. Parvari R, Weinstein Y, Ehrlich S, Steinitz M, Carmi R. Linkage localization of the thoraco-abdominal syndrome (TAS) gene to Xq25-26. *Am J Med Genet* 1994;49:431-4.
11. Parvari R, Carmi R, Weissenbach J, Pilia G, Mumm S, Weinstein Y. Refined genetic mapping of X-linked thoracoabdominal syndrome. *Am J Med Genet* 1996;61:401-2.
12. Nanda S, Nanda S, Agarwal U, Sen J, Sangwan K. Cantrell's syndrome - report of two cases with one atypical variant. *Arch Gynecol Obstet* 2003;268:331-2.
13. Alanbay İ, Çoksuer H, Ercan M, Karaşahin E, Karaca RE, Fidan U. Cantrell pentalojisi: Olgu sunumu. *Van Tıp Dergisi* 2012;19:133-6.
14. Loureiro T, Oliveira C, Aroso J, Ferreira MJ, Vieira J. Prenatal sonographic diagnosis of a rare Cantrell's pentalogy variant with associated open neural tube defect - a case report. *Fetal Diagn Ther* 2007;22:172-4.
15. Polat I, Gul A, Aslan H, Cebeci A, Ozseker B, Caglar B, Ceylan Y. Prenatal diagnosis of pentalogy of Cantrell in three cases, two with craniorachischisis. *J Clin Ultrasound* 2005;33:308-11.
16. Güven MA, Ceylaner G, Ceylaner S, Coşkun A, Bayazıt H. Prenatal tanısı konmuş Cantrell pentalojisi olgusu: Ensefalo-selin eşilik ettiđi nadir bir varyant. *TJOD Dergisi* 2009;6:123-7.